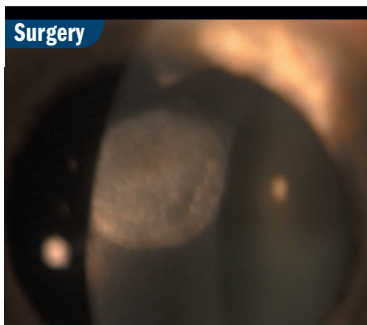

HOW EPITHELIUM PLAYS CRUCIAL OUTCOMES ROLE

IN THIS LATEST “Gloves Off with Gulani” column, Arun C. Gulani, MD, MS, considers how epithelial-based refractive surgery can allow ophthalmologists to achieve unprecedented vision results with the least-invasive procedures in even the most complex cases. Dr. Gulani continues to collect data from across the spectrum of refractive procedure/complication referrals to prepare a next-generation atlas.

(See story on page 8 : Epithelial)

Drug Therapy

RESTORING RETINAL CELLS TO PROPER FUNCTION IN LCA

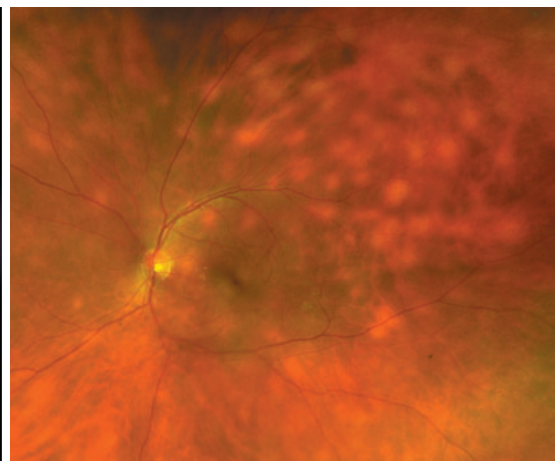
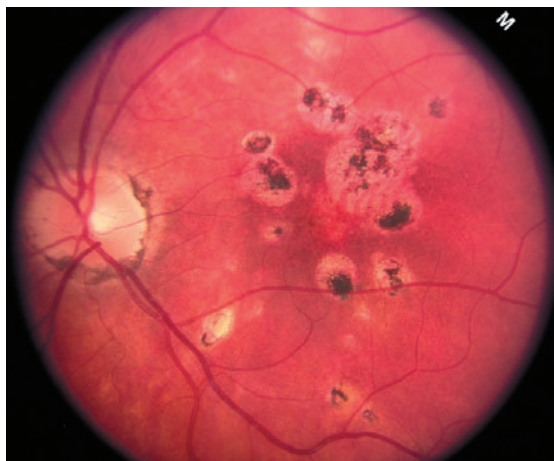A RESEARCH team at the University of Wisconsin School of Medicine and Public Health has shown that two novel approaches—read-through therapy and gene augmentation—for treating Leber’s congenital amaurosis may be effective in restoring the function of a vital component of healthy vision.

(See story on page 27 : Retinal defect)

► OphthalmologyTimes.com

Managing uveitic macular edema

Intravitreal triamcinolone acetonide, dexamethasone implant superior for regional treatment of disorder



IN VIEW Left: Fundus photo of an eye with multifocal choroiditis with macular edema. Right: Fundus photograph of Birdshot chorioretinitis with macular edema. (Images courtesy of Michael Altaweel, MD, on behalf of the MUST research group)

By Lynda Charters;

Reviewed by Jennifer E. Thorne, MD, PhD

MACULAR EDEMA is a common complication in patients with uveitis—so much so that about 40% of patients who participated in the Multicenter Uveitis Steroid Treatment (MUST) Trial had baseline uveitic macular edema. Though it can be treated and controlled, macular edema also can be stubborn, require additional treatment, and worse yet, compromise sight.

The results of the PeriOcular versus INTravitreal corticosteroids for Uveitic Macular Edema (POINT) study—a comparison of the regional go-to cortico-

steroids for uveitic macular edema—indicated that direct injection of corticosteroids into the eye was superior to a therapy that is administered periocularly, said Jennifer E. Thorne, MD, PhD.

Interestingly, an intravitreal dexamethasone implant was not associated with lower rates of IOP elevations as expected.

This study originated out of the recognition that few comparisons of the common treatments for uveitic macular edema had been undertaken, and the best and safest of the regional corticosteroids had yet to be determined, said Dr. Thorne, the Cross Family Professor of Ophthalmology, and chief, Division of Ocular Immunology, Wilmer Eye Institute, and professor of epidemiology, Johns Hopkins Bloomberg School of Public Health, Baltimore.

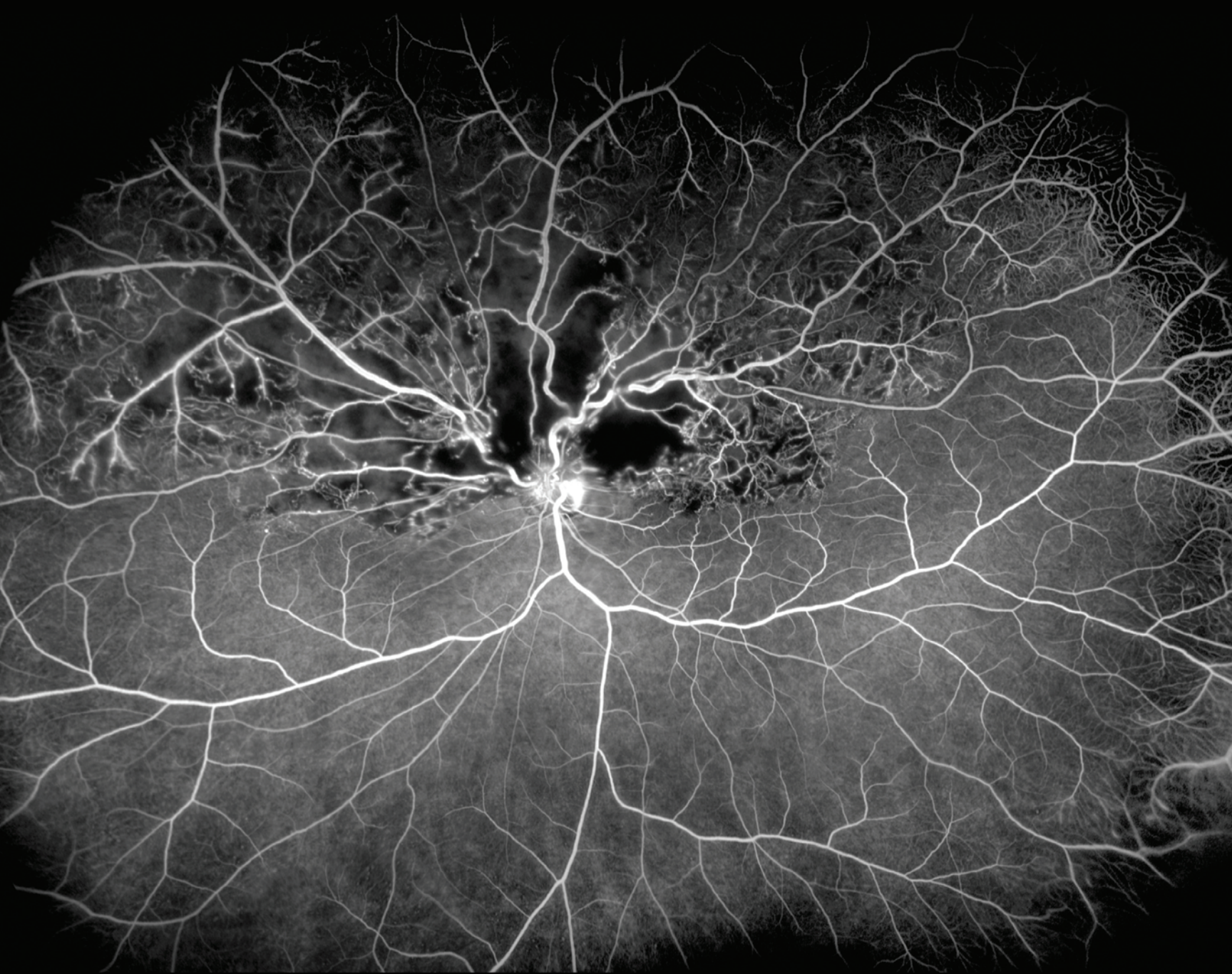
Therapies frequently used in this patient popula-

(Continues on page 18 : Uveitic)



GENE-EDITED BABIES

The next ‘designer’ baby could be a future ophthalmologist **PAGE 5**



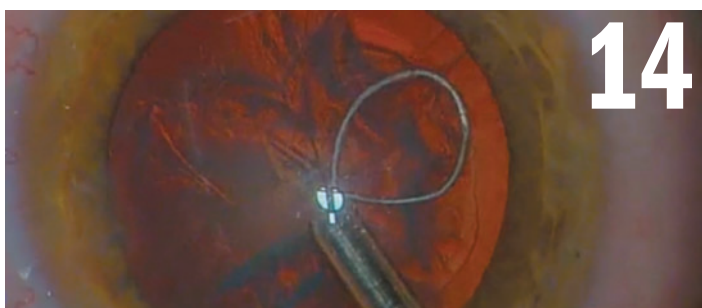
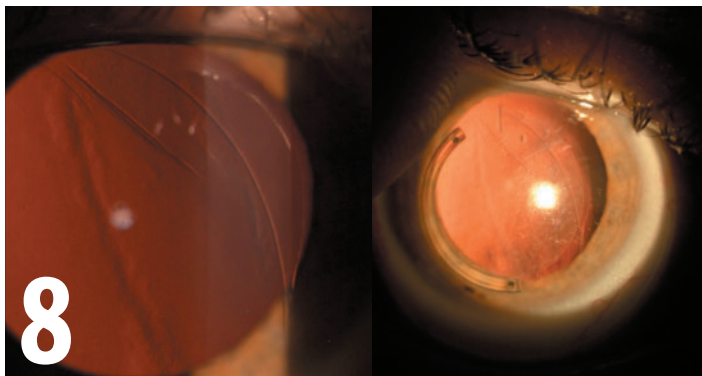
► **optomap[®]** Image beyond the vortex vessels
in less than ½ a second

the **ONLY** ultra-widefield single-capture *fa* image

Find out more at www.optos.com

Contact us to put optomap in your practice, call 800-854-3039 or email BDS@optos.com





25

Special Report

24 IL-6 INHIBITION SHOWS PROMISE FOR UVEITIS

Sarilumab may be effective in controlling inflammation, improving macular edema in non-infectious uveitic patients

Clinical Diagnosis

25 VISION-SCREENING TOOLS FOR CHILDREN WORLDWIDE

Efficient vision screening methods will increase likelihood that kids receive corrective treatment when they need it

Drug Therapy

27 STEM CELLS, GENE THERAPY MAKE WAVES IN RESEARCH

Study identifies LCA16 disorder as nonsense mutation; may be treated with breakthrough therapies in the future

In This Issue

5 EDITORIAL

28 MARKETPLACE

32 FOCAL POINTS

What's Trending

See what the ophthalmic community is reading on *OphthalmologyTimes.com*

1 Laser cataract surgery makes complex cases routine
<http://bit.ly/2EeoMq8>

2 Dry eye strategies from lab to clinic
<http://bit.ly/2tFg6o7>

3 Triggerfish pressure sensor promising
<http://bit.ly/2TPYQYE>

4 5 ways to turn online customer complaints into 'gifts'
<http://bit.ly/2H7Ntb5>

Digital App

Introducing the *Ophthalmology Times* app for iPad and iPhone. Download it for free today at OphthalmologyTimes.com/OTapp.

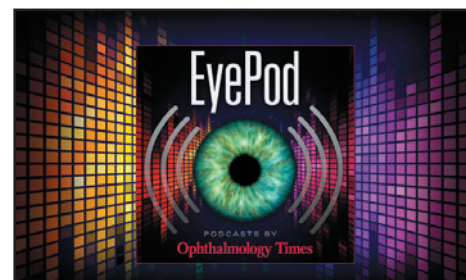


eReport

Sign up for *Ophthalmology Times*' weekly eReport at <https://bit.ly/2H4IBDu>



Podcast



In episode 4, Christopher F. Wood, MD, discusses why learning new technology for floater treatments is vital to the profession, and why everyone should strive to learn how to use to budding technologies. Listen at www.OphthalmologyTimes.com/EyePod

Facebook

Like *Ophthalmology Times* at Facebook.com/OphthalmologyTimes

Ophthalmology Times MISSION STATEMENT

Ophthalmology Times is a physician-driven media brand that presents cutting-edge advancements and analysis from around the world in surgery, drug therapy, technology, and clinical diagnosis to elevate the delivery of progressive eye health from physician to patient.

Ophthalmology Times' vision is to be the leading content resource for ophthalmologists.

Through its multifaceted content channels, *Ophthalmology Times* will assist physicians with the tools and knowledge necessary to provide advanced quality patient care in the global world of medicine.

CHIEF MEDICAL EDITOR Peter J. McDonnell, MD Wilmer Eye Institute Johns Hopkins University Baltimore, MD

ASSOCIATE MEDICAL EDITORS

Dimitri Azar, MD

University of Illinois, Chicago
Chicago, IL

Anne L. Coleman, MD
Jules Stein Eye Institute, UCLA
Los Angeles, CA

Ernest W. Kormmehl, MD

Harvard & Tufts Universities
Boston, MA

Robert K. Maloney, MD
Los Angeles, CA

Joan Miller, MD

Massachusetts Eye & Ear
Infirmary
Harvard University
Boston, MA

Randall Olson, MD

University of Utah
Salt Lake City, UT

Robert Osher, MD

University of Cincinnati
Cincinnati, OH

Anterior Segment/Cataract Cornea/External Disease

Ashley Behrens, MD
Wilmer Eye Institute, Johns Hopkins University
Baltimore, MD

Elizabeth A. Davis, MD
University of Minnesota,
Minneapolis, MN

Uday Devgan, MD
Jules Stein Eye Institute, UCLA
Los Angeles, CA

Richard S. Hoffman, MD
Oregon Health & Science University
Portland, OR

Samuel Maskat, MD
Jules Stein Eye Institute, UCLA
Los Angeles, CA

Bartly J. Mondino, MD
Jules Stein Eye Institute, UCLA
Los Angeles, CA

Mark Packer, MD
Boulder, CO

Michael Raizman, MD
Massachusetts Eye & Ear, Harvard University Boston, MA

Ehsan "Ethan" Sadri, MD, FACS
Newport Beach, CA

Michael Snyder, MD
Cincinnati Eye Institute
Cincinnati, OH

Farrell "Toby" Tyson, MD
Cape Coral, FL

Glaucoma

Robert D. Fechtner, MD
SUNY Upstate Medical University
Syracuse, NY

Neeru Gupta, MD
University of Toronto
Toronto, Canada

Richard K. Parrish II, MD
Bascom Palmer Eye Institute, University of Miami
Miami, FL

Robert Ritch, MD
New York Eye & Ear Infirmary
New York, NY

Joel Schuman, MD
NYU Langone Medical Center
New York, NY

Kuldev Singh, MD

Stanford University
Stanford, CA

Joshua D. Stein, MD
University of Michigan
Ann Arbor, MI

Robert N. Weinreb, MD
Hamilton Glaucoma Center
University of California, San Diego

Neuro-Ophthalmology

Andrew G. Lee, MD
Blanton Eye Institute, Houston Methodist Hospital
Houston, TX

Oculoplastics/ Reconstructive Surgery

Robert Goldberg, MD
Jules Stein Eye Institute, UCLA
Los Angeles, CA

John T. LiVecchi, MD
University of Florida College of Medicine
Gainesville, FL

Shannah L. Merbs, MD
Wilmer Eye Institute, Johns Hopkins University
Baltimore, MD

Pediatric Ophthalmology

Norman B. Medow, MD
Albert Einstein College of Medicine
Bronx, NY

Jennifer Simpson, MD
University of California, Irvine
Irvine, CA

H. Jay Wisnicki, MD
New York Eye & Ear Infirmary, Beth Israel Medical Center,
Albert Einstein College of Medicine
New York, NY

Practice Management

Joseph C. Noreika, MD
Medina, OH

Frank Weinstock, MD
Boca Raton, FL

Refractive Surgery

William Culbertson, MD
Bascom Palmer Eye Institute, University of Miami
Miami, FL

Peter S. Hersh, MD

University of Medicine & Dentistry of New Jersey
Newark, NJ

Jonathan H. Talamo, MD
Harvard University
Boston, MA

Kazuo Tsubota, MD
Keio University School of Medicine
Tokyo, Japan

Retina/Vitreous

Stanley Chang, MD
Columbia University
New York, NY

David Chow, MD
University of Toronto
Toronto, Canada

Pravin U. Dugel, MD
Phoenix, AZ

Sharon Fekrat, MD
Duke University
Durham, NC

Julia Haller, MD
Wills Eye Institute, Thomas Jefferson University
Philadelphia, PA

Tarek S. Hassan, MD
Oakland University
Rochester, MI

Michael Ip, MD
Doheny Eye Institute
Los Angeles, CA

Carl D. Regillo, MD
Wills Eye Institute, Thomas Jefferson University
Philadelphia, PA

Lawrence J. Singerman, MD
Case Western Reserve University
Cleveland, OH

Uveitis

Emmett T. Cunningham Jr., MD, PhD
Stanford University
Stanford, CA

Chief Medical Editors-Emeritus

Jack M. Dodick, MD
New York University School of Medicine
New York, NY (1976-1996)

David R. Guyer, MD
New York, NY (1996-2004)

OFFICIAL PUBLICATION SPONSOR OF



Ophthalmology Times

MARCH 1, 2019 ■ VOL. 44, NO. 4

CONTENT

Chief Medical Editor Peter J. McDonnell, MD

Group Editorial Director Sheryl Stevenson
sheryl.stevenson@ubm.com 440/891-2625

Associate Editor Julianne Mobilian
julianne.mobilian@ubm.com 440/891-2608

Design Director Robert McGarr

Senior Graphic Designer Lecia Landis

Graphic Designer Steph Bentz

Anterior Segment Techniques
Ernest W. Kormmehl, MD

coding.doc L. Neal Freeman, MD, MBA

Money Matters John J. Grande, Traudy F. Grande,
and John S. Grande, CFPs®

Neuro-Ophthalmology Andrew G. Lee, MD

Ophthalmic Heritage Norman B. Medow, MD

Tech Talk H. Jay Wisnicki, MD

Uveitis Update
Emmett T. Cunningham Jr., MD, PhD, MPH

PUBLISHING /ADVERTISING

President, MultiMedia Healthcare LLC
Thomas W Ehardt

Group Publisher Leonardo Avila
leonardo.avila@ubm.com 302/239-5665

Publisher Erin Schlussek Stever
erin.schlussek@ubm.com 215/962-5399

National Account Manager Cherie Pearson
cherie.pearson@ubm.com 609/636-0172

Account Manager, Recruitment Advertising
Joanna Shippoli joanna.shippoli@ubm.com
440/891-2615

Sales Director, Digital Media Don Berman
don.berman@ubm.com 203/523-7013

Reprints Licensing and Reuse of Content: Contact our official partner, Wright's Media, about available usages, license fees, and award seal artwork at Advanstar@wrightsmedia.com for more information. Please note that Wright's Media is the only authorized company that we've partnered with for MultiMedia Healthcare materials.

Permissions/International Licensing
Jillyn Frommer jillyn.frommer@ubm.com
732/346-3007

PRODUCTION

Production Director Karen Lenzen
klenzen@hcl.com 218/740-6371

AUDIENCE DEVELOPMENT

Audience Development Manager Kelly Kemper
kelly.kemper@ubm.com 612/253-2039

MultiMedia Healthcare LLC provides certain customer contact data (such as customers' names, addresses, phone numbers, and e-mail addresses) to third parties who wish to promote relevant products, services, and other opportunities that may be of interest to you. If you do not want MultiMedia Healthcare LLC to make your contact information available to third parties for marketing purposes, simply call toll-free 866-529-2922 between the hours of 7:30 a.m. and 5 p.m. CST and a customer service representative will assist you in removing your name from MultiMedia Healthcare LLC's lists. Outside the U.S., please phone 218-740-6477.

Ophthalmology Times does not verify any claims or other information appearing in any of the advertisements contained in the publication, and cannot take responsibility for any losses or other damages incurred by readers in reliance of such content.

Ophthalmology Times cannot be held responsible for the safekeeping or return of unsolicited articles, manuscripts, photographs, illustrations or other materials.

Ophthalmology Times is a member of the Association of Independent Clinical Publications Inc.

Library Access Libraries offer online access to current and back issues of *Ophthalmology Times* through the EBSCO host databases.

To subscribe, call toll-free 888-527-7008. Outside the U.S. call 218-740-6477.



Ophthalmology Times Industry Council

Leslie Amodi
Optos Inc., Vice President of Global Product
Marketing

Rahim K. Hirji, RPh
Omeros Corp., Director - Marketing

Neil Levine
Regeneron Healthcare Solutions
Executive Director, Marketing
Ophthalmology

Cody McKenzie
Glaukos, Director - U.S. Marketing

Tom Mitro
Aerie Pharmaceuticals
President and Chief Operating Officer

Brian O'Neal
Alcon Laboratories Inc., Head of Marketing
- U.S. Surgical

Ram Palanki
Santen, Senior Vice President of
Commercial, Americas

John Saharek
Imprimis Pharmaceuticals, Chief
Commercial Officer

Erin Schallhorn
Carl Zeiss Meditec, Sr. Director, Medical
Affairs and Professional Education

Julie Speed
Johnson & Johnson Vision, Sr. Director of
Marketing Americas, Surgical

Tracy Valorie
Bausch + Lomb, US Pharmaceuticals and
Surgical
Valeant Pharmaceuticals North America,
LLC
Sr. Vice President and General Manager

How to Contact Ophthalmology Times

Editorial
Millennium Place East
25115 Country Club Blvd.
North Olmsted, OH 44070
440/826-2800, FAX: 440/756-5227

Subscription Services
Toll-Free: 888/527-7008 or
218/740-6477
FAX: 218/740-6417

Advertising
485 Route 1 South
Building F, Suite 210,
Iselin, NJ 08830-3009
732/596-0276, FAX: 732/596-0003

Production
131 W. First St.
Duluth, MN 55802-2065
800/346-0085
FAX: 218/740-7223, 218/740-6576

Gene-edited babies

The next 'designer' baby could be a future ophthalmologist



By Peter J. McDonnell, MD

director of the Wilmer Eye Institute, Johns Hopkins University School of Medicine, Baltimore, and chief medical editor of *Ophthalmology Times*.

He can be reached at 727 Maumenee Building 600 N. Wolfe St. Baltimore, MD 21287-9278
Phone: 443/287-1511 Fax: 443/287-1514
E-mail: pmcdonn1@jhmi.edu

NO DOUBT, one is aware of controversy surrounding the creation of "designer babies."

Experts debate vigorously whether it is ethical, moral, or legal to alter the genetic library of a human embryo. Many argue this should be forbidden—at least for now—until we better understand the science and have more time to reflect on the implications of attempting such work.

The discourse splashed across the headlines recently when a scientist in China, He Jiankui, PhD, announced that he had done exactly this using CRISPR-Cas9 technology. The first (and reportedly also second) designer human baby was created with the intention of making it resistant to infection with HIV.

COULD DESIGNER BABIES SOON BE OUR REALITY?

Before our society goes down this path, I wish to offer a few words of caution. What all the debate so far has failed to grasp is that designer babies, if nurtured over many, many years in absurdly expensive undergraduate universities followed by more years in incredibly expensive medical schools, and then trained for many more years in internships, residency programs, and fellowships, have the potential to one day become—yes, that's right—"designer ophthalmologists."

Given this sobering fact, it would be wrong to give a green light to implementing this genetic technology until someone has carefully considered what should be the exact characteristics of these designer ophthalmologists.

I've given this careful thought and present the results of my analysis (to the best I can read my handwriting on the cocktail napkin from last night). Presuming we can learn what genes to insert to create these desired effects, the ideal "designer ophthalmologist" should:

Be two-faced: So one empathic appearing face is looking at the patient while the other "real" face is staring at the computer screen while documenting in the electronic medical record.

Be three-handed: So they can do 50% more bevacizumab injections per hour in clinic.

Be illogical: So the Byzantine rules and regulations imposed on us doctors by insurers and regulators will seem reasonable and not upsetting.

Have led a sheltered life: So the Chief Medical Editor's columns in *Ophthalmology Times* impress them as being witty.

Be impervious to pain: So they can enjoy the OKAPs, board examinations, and maintenance of certification programs.

Possess a prodigious memory: So they can memorize all the causes of white-dot syndromes in the retina in order to pass their board examinations and commit to memory as many orthopedic surgeon jokes as possible so they can amuse themselves and others.

Have a large rear end with wheels: So they can examine patients and operate without first having to find a stool.

Have no ears: So they can't hear what those people on political talk shows are saying.

Be rich: So they can afford to pay their American Academy of Ophthalmology dues.

Be generous: So they can forgive their department chairs for any cranky comments during residency and make donations to the department once they become wealthy ophthalmologists.


Have three eyes: So the extra eye can see the humor and fun in a typical day of patients.

Have two hearts: So one can pump blood while allowing the other to fully concentrate on feeling the joy that comes from providing compassionate care to his/her patients. ■

Reference

- <https://nypost.com/2018/12/12/making-designer-babies-without-ethics-is-a-recipe-for-disaster/>

THE CYCLE OF INFLAMMATION IN DRY EYE DISEASE²




Ocular Surface Stress



Inflammation



Tear Film Instability



Signs & Symptoms



XIIDRA MAY INTERRUPT THE CYCLE OF INFLAMMATION CENTRAL TO DRY EYE DISEASE^{1,2}

The exact mechanism of action of Xiidra in Dry Eye Disease is not known.¹

Xiidra blocks the interaction of ICAM-1 and LFA-1, which is a key mediator of the inflammation central to Dry Eye Disease. *In vitro* studies have shown that Xiidra may inhibit the recruitment of previously activated T cells, the activation of newly recruited T cells, and the release of pro-inflammatory cytokines.¹

.....
Check out Xiidra-ECP.com
.....

.....
Indication

Xiidra[®] (lifitegrast ophthalmic solution) 5% is indicated for the treatment of signs and symptoms of dry eye disease (DED).

.....
Important Safety Information

Xiidra is contraindicated in patients with known hypersensitivity to lifitegrast or to any of the other ingredients.

In clinical trials, the most common adverse reactions reported in 5-25% of patients were instillation site irritation, dysgeusia and reduced visual acuity. Other adverse reactions reported in 1% to 5% of the patients were blurred vision, conjunctival hyperemia, eye irritation, headache, increased lacrimation, eye discharge, eye discomfort, eye pruritus and sinusitis.

To avoid the potential for eye injury or contamination of the solution, patients should not touch the tip of the single-use container to their eye or to any surface.

Contact lenses should be removed prior to the administration of Xiidra and may be reinserted 15 minutes following administration.

Safety and efficacy in pediatric patients below the age of 17 years have not been established.

For additional safety information, see accompanying Brief Summary of Safety Information on the adjacent page and Full Prescribing Information on Xiidra-ECP.com.

References:

1. Xiidra [Prescribing Information]. Lexington, MA: Shire US. 2. TFOS DEWS II Research Subcommittee. Report of the Research Subcommittee of the Tear Film & Ocular Surface Society Dry Eye WorkShop II (2017). *Ocul Surf.* 2017;15(3):269-275.





BRIEF SUMMARY:

Consult the Full Prescribing Information for complete product information.

INDICATIONS AND USAGE

Xiidra® (lifitegrast ophthalmic solution) 5% is indicated for the treatment of the signs and symptoms of dry eye disease (DED).

DOSAGE AND ADMINISTRATION

Instill one drop of Xiidra twice daily (approximately 12 hours apart) into each eye using a single-use container. Discard the single-use container immediately after using in each eye. Contact lenses should be removed prior to the administration of Xiidra and may be reinserted 15 minutes following administration.

CONTRAINDICATIONS

Xiidra is contraindicated in patients with known hypersensitivity to lifitegrast or to any of the other ingredients in the formulation.

ADVERSE REACTIONS

Clinical Trials Experience

Because clinical studies are conducted under widely varying conditions, adverse reaction rates observed in clinical studies of a drug cannot be directly compared to rates in the clinical trials of another drug and may not reflect the rates observed in practice. In five clinical studies of dry eye disease conducted with lifitegrast ophthalmic solution, 1401 patients received at least 1 dose of lifitegrast (1287 of which received lifitegrast 5%). The majority of patients (84%) had ≤ 3 months of treatment exposure. 170 patients were exposed to lifitegrast for approximately 12 months. The majority of the treated patients were female (77%). The most common adverse reactions reported in 5-25 % of patients were instillation site irritation, dysgeusia and reduced visual acuity. Other adverse reactions reported in 1% to 5% of the patients were blurred vision, conjunctival hyperemia, eye irritation, headache, increased lacrimation, eye discharge, eye discomfort, eye pruritus and sinusitis.

Postmarketing Experience

The following adverse reactions have been identified during postapproval use of Xiidra. Because these reactions are reported voluntarily from a population of uncertain size, it is not always possible to reliably estimate their frequency or establish a causal relationship to drug exposure.

Rare cases of hypersensitivity, including anaphylactic reaction, bronchospasm, respiratory distress, pharyngeal edema, swollen tongue, and urticaria have been reported. Eye swelling and rash have been reported.

USE IN SPECIFIC POPULATIONS

Pregnancy

There are no available data on Xiidra use in pregnant women to inform any drug associated risks. Intravenous (IV) administration of lifitegrast to pregnant rats, from pre-mating through gestation day 17, did not produce teratogenicity at clinically relevant systemic exposures. Intravenous administration of lifitegrast to pregnant rabbits during organogenesis produced an increased incidence of omphalocele at the lowest dose

tested, 3 mg/kg/day (400-fold the human plasma exposure at the recommended human ophthalmic dose [RHOD], based on the area under the curve [AUC] level). Since human systemic exposure to lifitegrast following ocular administration of Xiidra at the RHOD is low, the applicability of animal findings to the risk of Xiidra use in humans during pregnancy is unclear.

Animal Data

Lifitegrast administered daily by intravenous (IV) injection to rats, from pre-mating through gestation day 17, caused an increase in mean preimplantation loss and an increased incidence of several minor skeletal anomalies at 30 mg/kg/day, representing 5,400-fold the human plasma exposure at the RHOD of Xiidra, based on AUC. No teratogenicity was observed in the rat at 10 mg/kg/day (460-fold the human plasma exposure at the RHOD, based on AUC). In the rabbit, an increased incidence of omphalocele was observed at the lowest dose tested, 3 mg/kg/day (400-fold the human plasma exposure at the RHOD, based on AUC), when administered by IV injection daily from gestation days 7 through 19. A fetal No Observed Adverse Effect Level (NOAEL) was not identified in the rabbit.

Lactation

There are no data on the presence of lifitegrast in human milk, the effects on the breastfed infant, or the effects on milk production. However, systemic exposure to lifitegrast from ocular administration is low. The developmental and health benefits of breastfeeding should be considered, along with the mother's clinical need for Xiidra and any potential adverse effects on the breastfed child from Xiidra.

Pediatric Use

Safety and efficacy in pediatric patients below the age of 17 years have not been established.

Geriatric Use

No overall differences in safety or effectiveness have been observed between elderly and younger adult patients.

NONCLINICAL TOXICOLOGY

Carcinogenesis, Mutagenesis, Impairment of Fertility

Carcinogenesis: Animal studies have not been conducted to determine the carcinogenic potential of lifitegrast.

Mutagenesis: Lifitegrast was not mutagenic in the *in vitro* Ames assay. Lifitegrast was not clastogenic in the *in vivo* mouse micronucleus assay. In an *in vitro* chromosomal aberration assay using mammalian cells (Chinese hamster ovary cells), lifitegrast was positive at the highest concentration tested, without metabolic activation.

Impairment of fertility: Lifitegrast administered at intravenous (IV) doses of up to 30 mg/kg/day (5400-fold the human plasma exposure at the recommended human ophthalmic dose (RHOD) of lifitegrast ophthalmic solution, 5%) had no effect on fertility and reproductive performance in male and female treated rats.



Manufactured for: Shire US Inc., 300 Shire Way, Lexington, MA 02421. For more information, go to www.Xiidra.com or call 1-800-828-2088. Marks designated ® and ™ are owned by Shire or an affiliated company. ©2018 Shire US Inc. SHIRE and the Shire Logo are trademarks or registered trademarks of Shire Pharmaceutical Holdings Ireland Limited or its affiliates. Patented: please see <https://www.shire.com/legal-notice/product-patents> Last Modified: 01/2018 S33769

ETM valuable in planning, evaluation of outcomes

Quantitative measurement indicates corneal epithelium plays crucial role in outcomes

Gloves Off with Gulani By *Arun C. Gulani, MD, MS, and Aaisha A. Gulani, BS*

FOR MANY YEARS, I have been traveling the world teaching surgeons about Corneoplastique—my philosophy and practice whereby any eye with visual potential can attain 20/20 or better unaided vision with individualized use of the entire range of ocular surface, corneal, and intraocular techniques.¹

This approach focuses on the refractive endpoint of unaided emmetropia and considers the spectrum of available techniques in a holistic way to prepare and repair the eye.

As a result, virgin eyes with refractive error can achieve vision beyond 20/20, and nearly any post-surgical problem can be repaired to 20/20.

In addition, non-candidates—for reasons including corneal scar, thin cornea, ectasia, and irregular astigmatism—can be converted to candidates for pursuing excellent vision results.

ADDING EPITHELIAL THICKNESS MAPPING

A recent addition to this approach is epithelial thickness mapping (ETM).

ETM—an anterior segment optical coherence tomography (AS-OCT) mode available with certain OCT technology (iVue, iFusion, and Avanti, all from Optovue)—is the only FDA-approved, non-contact method of quantitatively measuring the corneal epithelium and stroma.

With a large 9-mm scan, it maps epithelial patterns and irregularities that are associated with subclinical keratoconus and ectasia risk,² dry eye disease,³ and previous refractive surgery.^{4,5}

As such, ETM is a valuable tool for pre-surgery risk evaluation, surgical planning,

evaluation of outcomes, and enhancement procedure planning.

I have long suspected that the epithelium plays a significant role in quality of vision and refractive surgery outcomes. ETM enables me to document this.⁶

TAKE-HOME

Arun C. Gulani, MD, MS, and Aaisha A. Gulani, BS, share how epithelial-based refractive surgery can allow surgeons to achieve unprecedented vision results with the least-invasive procedures in even the most complex cases.

To further elucidate the role of the epithelium, I am mapping epithelial thickness before and after the Corneoplastique procedures.

ETM repeatedly indicates a strong correlation between vision and the smoothness of the epithelium.

The epithelium appears to smooth the anterior cornea and maximize the interplay of the eye's optical components despite underlying irregular stroma.

I believe this helps to explain the successful results

I've achieved over three decades using the least-invasive procedures to provide patients with life-changing quality of vision.⁷

Consider, for example, the following case examples.

CASE 1 UNAIDED 20/25 VISION FOR EYE WITH CENTRAL CORNEAL HERPETIC SCAR IN ONLY SEEING EYE

Based on multiple consultations with other surgeons, a 42-year-old male patient with a central corneal herpetic scar and 20/400 vision in his only seeing eye expected to require a corneal transplant to obtain usable vision.

Instead, given that his vision in that eye was correctable to 20/50, after a detailed informed consent, he elected to proceed with laser Corneoplastique (epithelium removal and modified excimer laser application) to refractively reshape the scar without treating the underlying cornea.

Despite the presence of residual scar, and no improvement in astigmatism, the patient's postoperative unaided vision is 20/25-.

ETM shows how the epithelium remodeled over the residual scar, essentially filling in the irregular area to smooth the anterior corneal surface.

Note that treating this eye based on corneal topography would have resulted in a misdirected treatment target. Topography was not a factor in light of the epithelial changes that occurred and the most important measure of success, which is the patient's final vision outcome and perceived improvement.

CASE 2 UNAIDED 20/10 VISION FOR A PREVIOUS CONTACT LENS WEARER

Based on a thin cornea, high-myopic astigmatism, and predisposition for dry eye, I recommended advanced surface ablation for this 34-year-old female who desired freedom from contact lenses.

Her postoperative unaided visual acuity is 20/10. She reports 10/10 satisfaction with the improvement, especially with night vision, which, she notes is much better than her previous night vision with contact lenses.

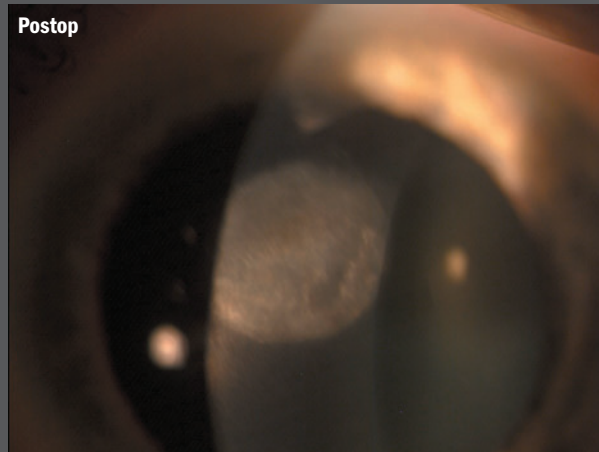
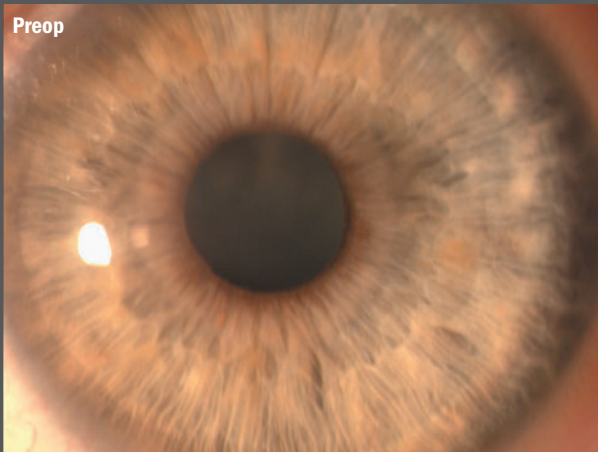
ETM of both eyes shows a regular contour of the epithelium, an indication of the importance of the epithelium in achievement of pristine vision.

CASE 3 UNAIDED 20/30 VISION FOR EYE WITH POSTERIOR CORNEAL SCARS

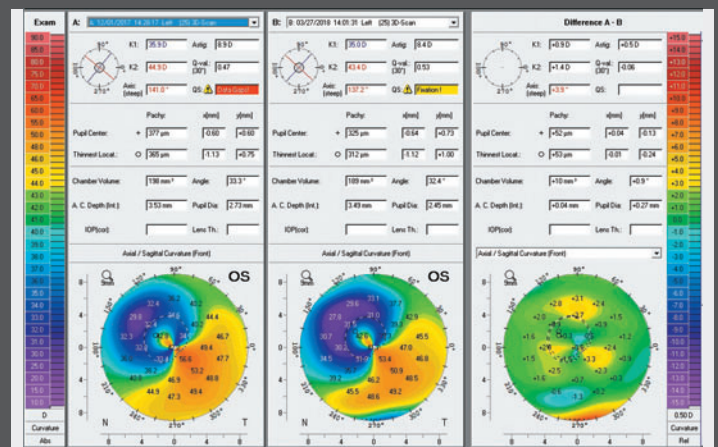
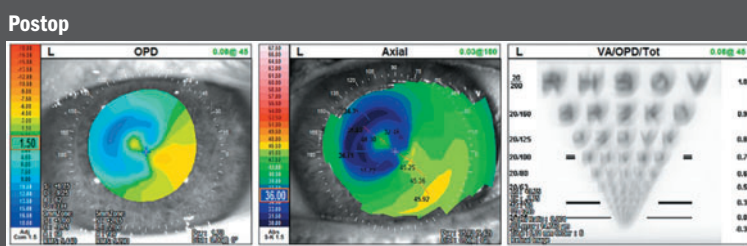
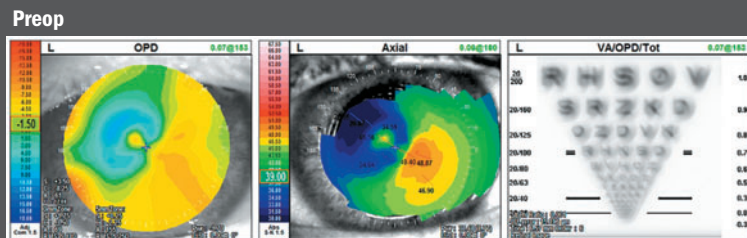
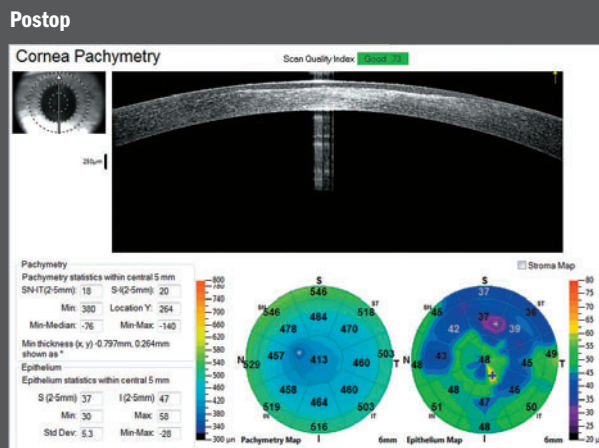
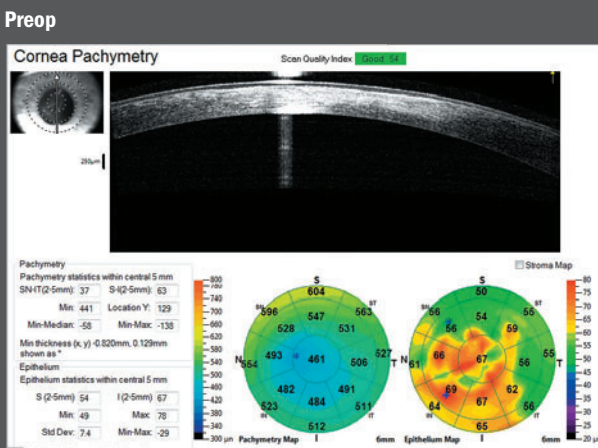
Forceps trauma suffered at birth caused a posterior Descemet's tear and posterior corneal scars in the right eye of this 23-year-old male. His cornea was ectatic, he had 5.2 D of irregular astigmatism and visual acuity of 20/400, which was correctable to 20/50.

Rather than perform a lamellar trans-

CASE 1



Left. A 42-year-old male with a central corneal herpetic scar and 20/400 vision in his only seeing eye. Right. The patient's postoperative unaided vision is 20/25-.



ETM shows how the epithelium remodeled over the residual scar, essentially filling in the irregular area to smooth the anterior corneal surface. Note that treating this eye based on corneal topography would have resulted in a misdirected treatment target. Topography was not a factor in light of the epithelial changes that occurred and the most important measure of success, which is the patient's final vision outcome and perceived improvement.

plant to stabilize the cornea and improve its shape, I placed corneal inserts (Intacs, Addition Technology) with careful selection of incision axis.

The result was a nearly 4 D reduction in astigmatism (arrows) and unaided 20/30 vision. ETM shows a higher anterior regularity, apparently a compensatory mechanism for overriding the posterior corneal irregu-

larity, which is the likely explanation for the patient's subjective and objective vision improvement and extreme satisfaction.

CASE 4
UNAIDED 20/20 VISION WITH LASER FOLLOWING FAILED INTACS

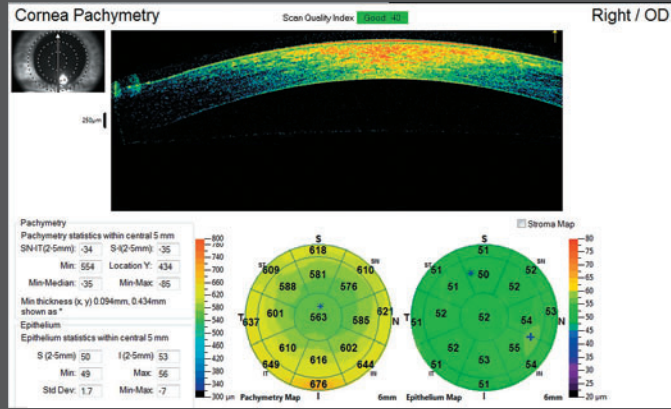
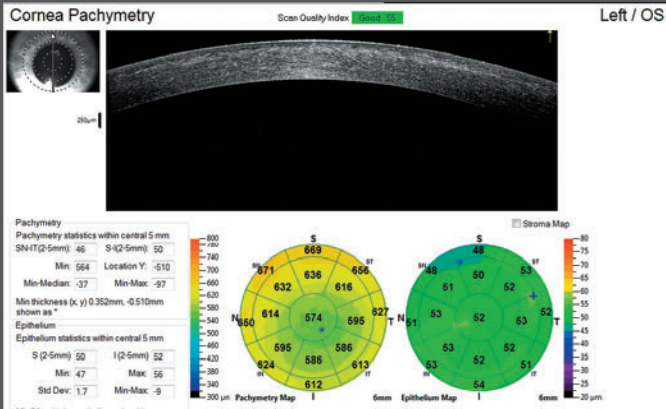
A 47-year-old female was referred to me after Intacs placed by her surgeon to ad-

dress keratoconus in the right eye extruded into the anterior chamber. The surgeon extracted the corneal inserts, which caused a scar.

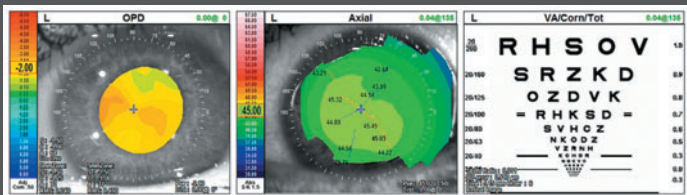
The previous surgeon had also performed corneal crosslinking, which stabilized the cornea and allowed me to re-shape it with laser Corneoplastique (the

Continues on page 10 : Case study

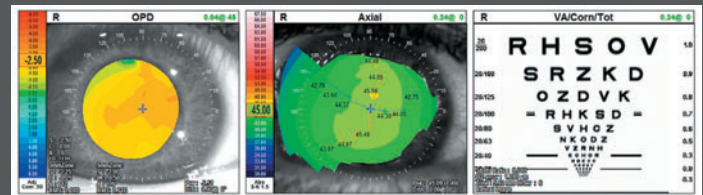
CASE 2



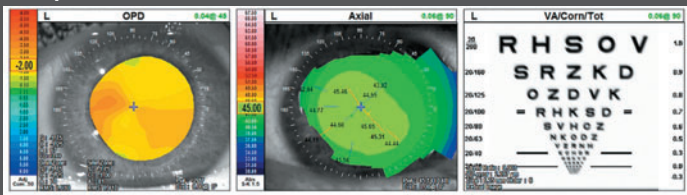
Preop



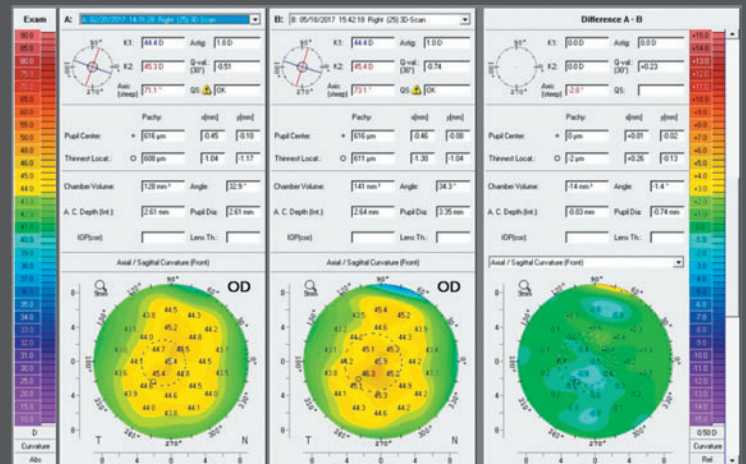
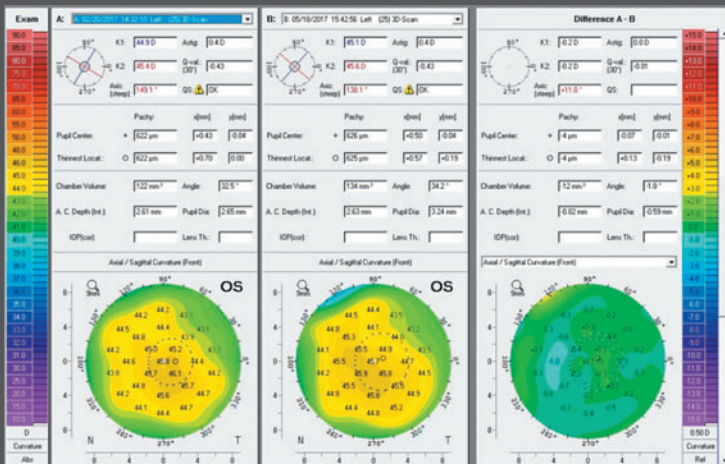
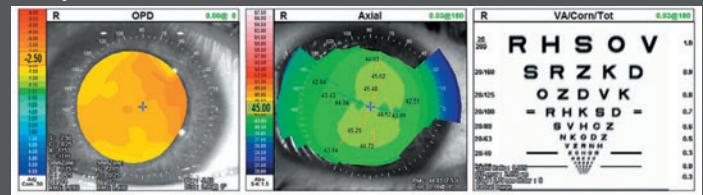
Preop



Postop



Postop



Unaided 20/10 vision for a previous contact lens wearer. ETM of both eyes shows a regular contour of the epithelium, an indication of the importance of the epithelium in achievement of pristine vision.

CASE STUDY

(Continued from page 9)

eye was refractable to 20/25) without disturbing the previous surgery. The outcome of the laser procedure is unaided 20/20 vision despite lack of change in astigmatism on topography.

Postoperative ETM shows the epithelium

remodeling to fill in not only the refractively induced corneal curvature but also the area of the scar and the uneven stromal thickness that is the hallmark of the keratoconus itself.

SEEING THE WHOLE PICTURE

Now is a good time for refractive surgeons to begin using ETM to understand the role of the epithelium in each case.

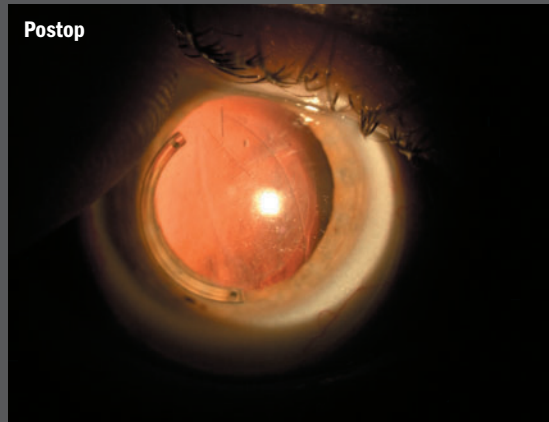
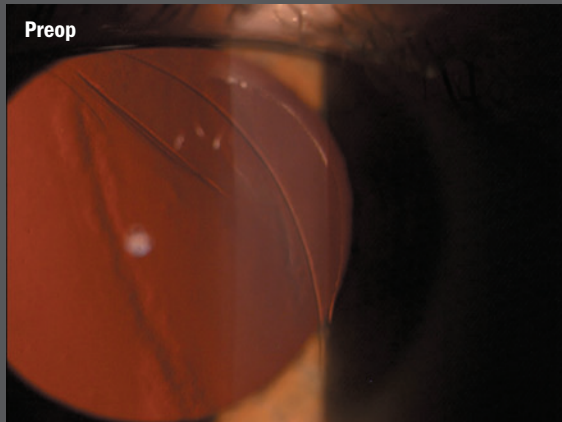
Developing an understanding of the dif-

ferent patterns and changes in the epithelium and how they impact patients' vision will move the field toward better outcomes, much like what occurred with the emergence of topography many years ago.

With my work involving Corneoplastique and ETM, I aim to confirm that epithelial-based refractive surgery can allow surgeons to achieve unprecedented vision results with the least-invasive procedures in even the most complex cases.

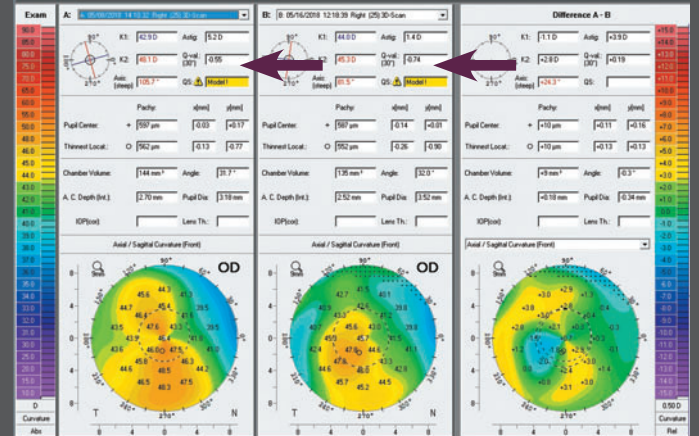
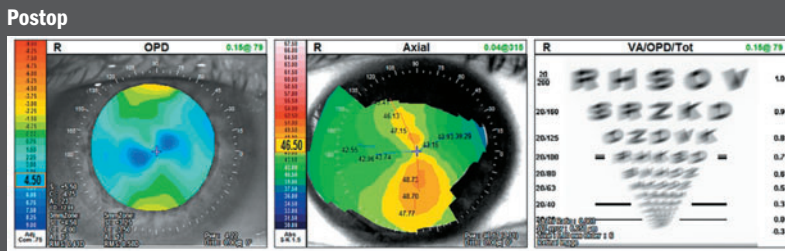
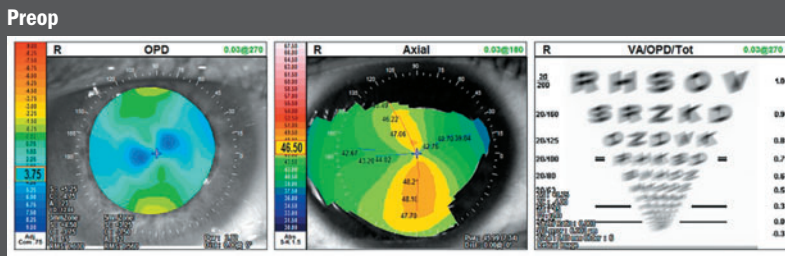
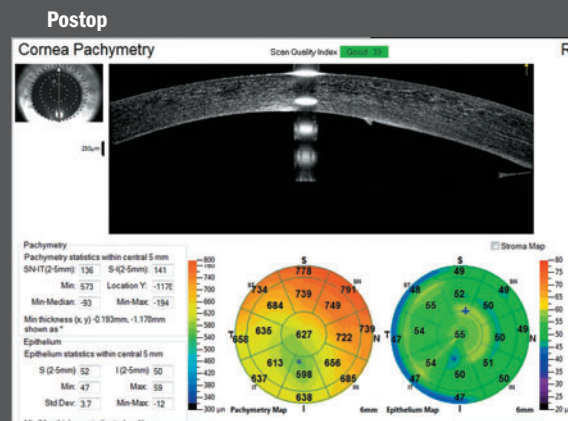
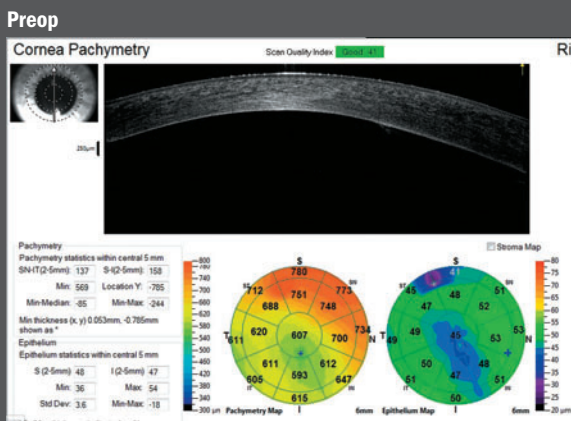
Looking beyond corneal shape to an-

CASE 3



Left. Forceps trauma suffered at birth caused a posterior Descemet's tear and posterior corneal scars in the right eye of this 23-year-old male. His cornea was ectatic, he had 5.2 D of irregular astigmatism and visual acuity of 20/400, which was correctable to 20/50.

Right. Rather than perform a lamellar transplant to stabilize the cornea and improve its shape, corneal inserts were placed with careful selection of incision axis.



The result was a nearly 4D reduction in astigmatism (arrows) and unaided 20/30 vision. ETM shows a higher anterior regularity, apparently a compensatory mechanism for overriding the posterior corneal irregularity, which is the likely explanation for the patient's subjective and objective vision improvement and extreme satisfaction.

other dominant impact factor in keratorefractive surgery, my practice is continuing to collect images and data from cases across the spectrum of refractive procedures and complications referred to us in order to potentially prepare a next-generation atlas.

The epithelium—seen in the past as the mole hill in the realm of vision correction—may be the mountain. ■



ARUN C. GULANI, MD, MS

E: gulanivision@aol.com

Dr. Gulani, an anterior segment specialist and creator of the Corneoplastique concept of vision correction, is the founder of Gulani Vision Institute in Jacksonville, FL.

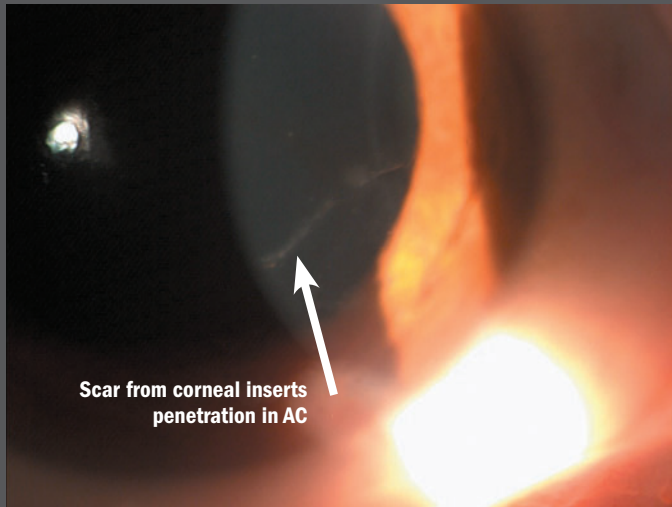


AAISHA A. GULANI is a senior at the University of Pennsylvania where she's concentrating on healthcare management and finance at the Wharton School of Business.

References

1. Gulani AC. Corneoplastique: Art of vision surgery. *Indian J Ophthalmol.* 2014; 62:3-11.
2. Li Y, Chamberlain W, Tan O, Brass R, Weiss JL, Huang D. Subclinical keratoconus detection by pattern analysis of corneal and epithelial thickness maps with optical coherence tomography. *J Cataract Refract Surg.* 2016;42:284-295.
3. Kanellopoulos AJ, Asimellis G. In vivo 3-dimensional corneal epithelial thickness mapping as an indicator of dry eye: preliminary clinical assessment. *Amer J Ophthalmol.* 2014;157:63-68.
4. Kanellopoulos AJ, Georgiadou S, Asimellis G. Objective

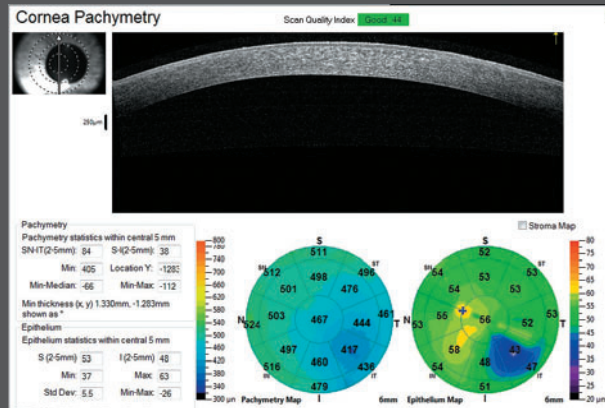
CASE 4



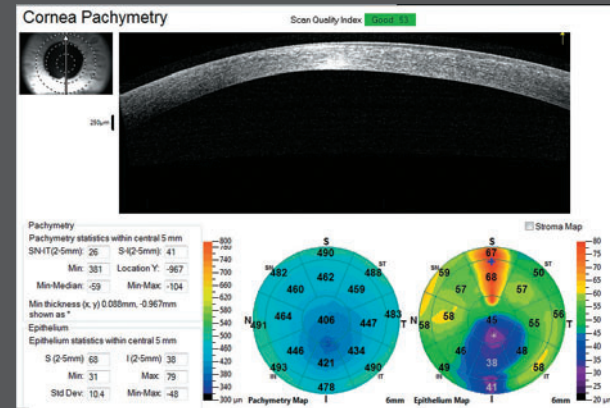
A 47-year-old female was referred after corneal inserts placed by her surgeon to address keratoconus in the right eye extruded into the anterior chamber. The surgeon extracted the corneal inserts, which caused a scar.

The outcome of the laser procedure is unaided 20/20 vision despite lack of change in astigmatism on topography.

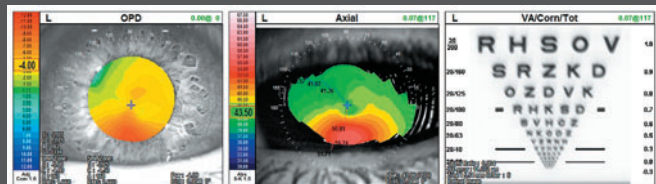
Preop



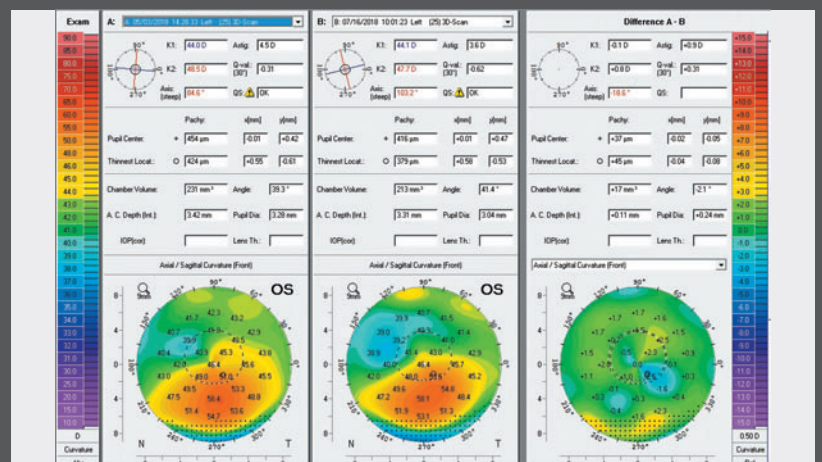
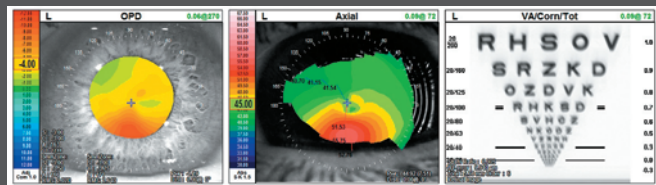
Postop



Preop



Postop



Postoperative ETM shows the epithelium remodeling to fill in not only the refractively induced corneal curvature but also the area of the scar and the uneven stromal thickness that is the hallmark of the keratoconus itself. (Images courtesy of Arun C. Gulani, MD, MS)

ETM VALUE

(Continued from page 11)

5. Tang M, Li Y, Huang D. Corneal epithelial remodeling after LASIK measured by Fourier-domain optical coherence tomography. *J Ophthalmol*. 2015;2015:860313.

6. Gulani AC. Irregular astigmatism to 20/20. Presentation at the International Refractive Surgery Congress, Shanghai, China, May 2018.
7. Gulani AC. Corneal re-shaping for irregular astigmatism: back to 20/20. Presentation at the Advanced Refractive Congress, Ft Lauderdale, FL, July 2018.

THE RIGHT ROUTE CAN
MAKE ALL THE DIFFERENCE



**Access retinal disease directly
through the suprachoroidal space.**

The suprachoroidal space provides a novel approach to drug delivery, offering new opportunities to access diseased tissue in the back of the eye.¹

▶ See the potential at SuprachoroidalSpace.com

Reference: 1. Chiang B, Jung JH, Prausnitz MR. The suprachoroidal space as a route of administration to the posterior segment of the eye. *Adv Drug Deliv Rev.* 2018;126:58-66.

MMM-0038 02/19 © 2019 Clearside Biomedical, Inc.

More stable surgery may help better predict effective IOL position

Lens fragmentation device may avoid disrupting zonules, enhance refractive outcomes

By **Kenneth J. Hoffer, MD, FACS, and Gerald J. Roper, MD**; Special to Ophthalmology Times

EXACTING IOL power calculations are required to provide optimal refractive results to patients following cataract surgery.

One of the most common sources of error in these calculations remains the effective lens position (ELP). It is difficult to determine this exact healed postoperative axial position from preoperative biometric data.

The ELP may be reasonably estimated by the vector physics and mathematics of the latest IOL calculation formulas, though validating this specific parameter for error is limited by challenges in determining the postoperative axial IOL final lens position (FLP).

Going forward, swept-source ocular coherence tomography images on newer biometers may be able to help assess the accuracy of the ELP calculation parameter in the various formulas.

The FLP will be compared with the ELP estimates of the IOL axial position, presuming that surgical technique will not significantly influence zonular support.

We realize, however, that the surgery may well have an effect.

In eyes that have had previous corneal surgery, it is also challenging to determine the exact power of the cornea.¹

Formulas such as the Barrett Universal II, Haigis, Hoffer H-5, Holladay 2, Olsen, and others address more variables than in the past.²

ELP STILL SURGICAL CHALLENGE

For as many advances as surgeons have at their disposal, both diagnostically and in the operating room, accurately achieving the desired postoperative refractive remains a challenge.

Further, surgeons' willingness to fully embrace premium lens solutions for their patients depends upon their comfort level with their results. When patients are paying additionally for a truly refractive result from their implant surgery, surgeons are under pressure to nail outcomes precisely.

Disparities between the predicted ELP to the resultant FLP has been shown to contribute more than 35% of mean absolute error.³ It is the most common cause of residual refractive error, followed by postoperative refraction variability, preoperative axial length measurement, and pupillary size variation (Figure 1).

A factor influencing the FLP, compared with the ELP, may be zonular integrity. Any part of the cataract procedure that strains the zonules or works against their integrity may contribute to less stability of the fibrosed lens capsule axial position and thus to less predictability of the refractive result.

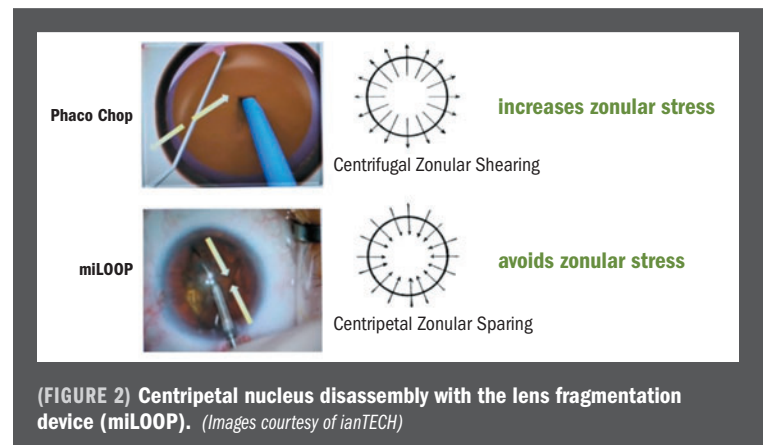
Current investigations suggest that when zonular integrity is better maintained for 360°, accuracy in achieving the refractive target seems to increase.

TAKE-HOME

A lens fragmentation device can help to maintain zonular integrity, which can improve refractive outcomes, explain Kenneth J. Hoffer, MD, FACS, and Gerald J. Roper, MD.

SOURCE OF ERROR	CONTRIBUTION TO MEAN ABSOLUTE ERROR (MAE)
Effective lens position: Preoperative estimation of postoperative intraocular lens (IOL) position	36%
Postoperative refraction variability	27%
Preoperative axial length measurement	17%
Pupil size variation	8%
Variability in IOL power	1%

(FIGURE 1) Prediction of effective lens position (ELP) is the most common contributor to residual refractive error.³



(FIGURE 2) Centripetal nucleus disassembly with the lens fragmentation device (miLOOP). (Images courtesy of ianTECH)

It would stand to reason that sagging due to zonular breaks or rupture would leave the lens in a different axial position and bearing from the anatomical predictions of ELP used to determine calculations.

Preoperative measurements that predict where the lens will sit after surgery presume intact zonules. Simply, if zonules break, ELP may become less accurate; that's our theory. By keeping the zonules intact, ELP prediction may be enhanced.

CLINICAL EXPERIENCE

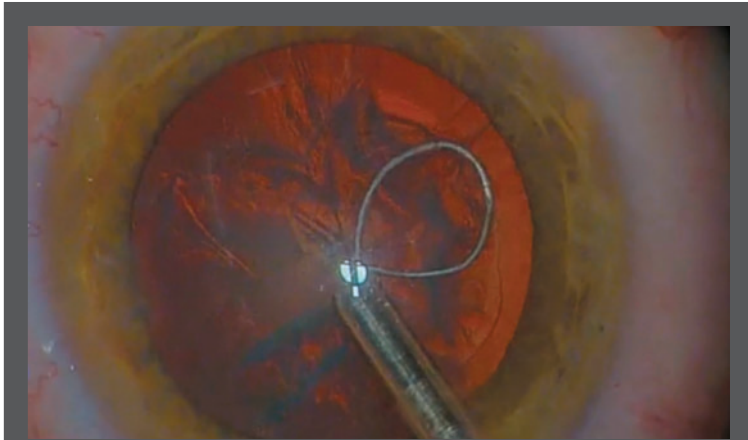
A recent comprehensive data set

overview of 374 cataract surgery patients at one of the author's practices (GJR) revealed a mean absolute error was 0.23 D.

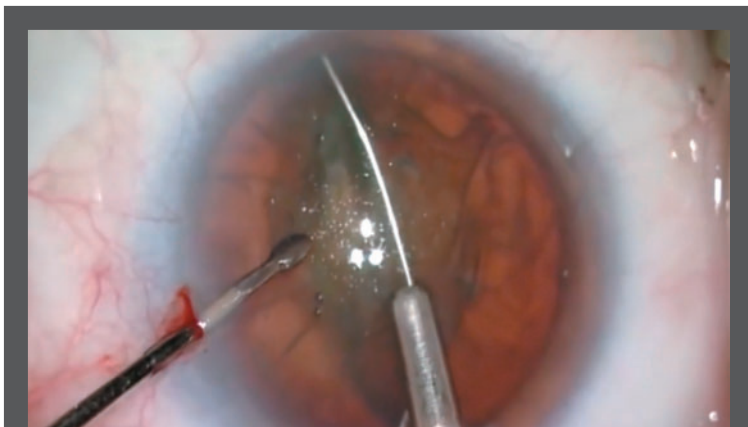
After considering the relationship between zonular integrity and ELP, the decision was made to incorporate the lens fragmentation device (miLOOP, Carl Zeiss Meditec/ianTECH).

The self-expanding, nitinol filament technology ensnares the nucleus allowing for full-thickness fragmentation.

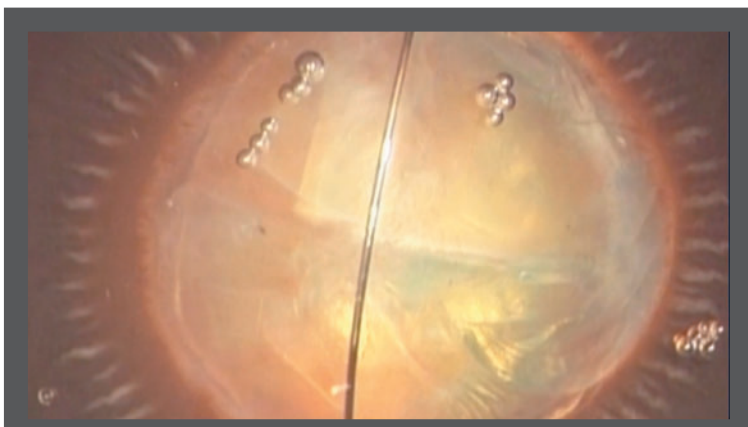
It works independent of phaco energy, using instead centripetal (out-in) disassembly to minimize



(FIGURE 3) The lens fragmentation device is being opened within the anterior chamber and edged under the anterior capsule to surround the nucleus.
(Images courtesy of ianTECH)



(FIGURE 4) The lens fragmentation device has been slid under the anterior capsule and brought midway to start halving the nucleus by retracting the loop.



(FIGURE 5) After halving the nucleus, the nucleus is rotated 90° to quarter it.
(Images courtesy of ianTECH)

capsular stress and cut the nucleus in half. It was hoped that routine use of the device would avoid disrupting zonules and improve excellent refractive outcomes.

The device's sweeping motion along the inside of the lens cap-

sule is a gentle maneuver, according to the surgeon (GJR).

There was no significant decrease in zonular integrity observed throughout the surgical cases, and the learning curve was relatively short.

Current investigations suggest that when zonular integrity is better maintained for 360°, accuracy in achieving the refractive target seems to increase.

A data review of the clinic's first 50 miLOOP cases for 8-week refractive outcomes, using otherwise usual protocol and identical criteria as previous cases. The mean absolute error dropped to 0.15 D.

MORE CONFIDENT RECOMMENDATIONS

With the lens fragmentation device, under the proper technique, there is little front to back or translational displacement of the lens when it is placed in the capsular bag (Figure 2).

By incorporating the lens fragmentation device, surgeons may enhance their cataract surgery process and move closer to delivering excellent refractive outcomes to patients (Figures 3 to 5).

More predictable results may allow surgeons to more fully participate in recommending and implanting premium IOL technology.

CONCLUSION

Maintaining zonular integrity may help conquer one of the issues that holds surgeons back from achieving more accurate refractive outcomes on a consistent basis.

The lens fragmentation device is a tool that may enhance zonular integrity and perhaps the refractive outcomes. These factors may help to ensure the lens is placed in its intended position. ■

References

1. Savini G, Hoffer KJ. Intraocular lens power calculation in eyes

with previous corneal refractive surgery. *Eye Vis (Lond)*. 2018;5:18. doi: 10.1186/s40662-018-0110-5. eCollection 2018.

2. Hoffer KJ, Savini G. Clinical results of the Hoffer H-5 formula in 2707 eyes: First 5th-generation formula based on gender and race. *Intl Ophthalmol Clin*. 2017;57:213-219. doi: 10.1097/IIO.000000000000183.
3. Norrby S. Sources of error in intraocular lens power calculation. *J Cataract Refract Surg*. 2008;34:368-376.



KENNETH J. HOFFER, MD

E: khoffermd@aol.com

Dr. Hoffer is a clinical professor of ophthalmology at Jules Stein Eye Institute,

University of California, Los Angeles. He did not indicate any proprietary interest in the subject matter.



GERALD R. ROPER, MD

E: ropergj@gmail.com

Dr. Roper is in private practice at Advanced Eye Care, Batesville, IN. Dr. Roper is a consultant to ianTECH.

BIOLOGICS MAY OFFER SYSTEMIC THERAPY OPTION FOR UVEITIS

One biologic response modifier has indication for uveitis; several in development to gain FDA approval

By Cheryl Guttman Krader; Reviewed by Eric B. Suhler, MD, MPH

Quoting a line from “Forrest Gump,” Eric B. Suhler, MD, MPH, suggested that use of novel biologic response modifiers (BRMs) for uveitis in the earlier stages of study may be “like a box of chocolates.” “You never know what you are going to get,” explained Dr. Suhler, chief of ophthalmology, VA Portland Health Care System, and professor of ophthalmology and public health, Oregon Health and Science University, Portland, OR. One BRM is FDA approved for the treatment of uveitis, and it is hoped others will follow. However, more experience with this therapeutic category is needed before BRMs are adopted as first-line options, Dr. Suhler noted.

take-home

► Treatment with a biologic response modifier (BRM) offers a more targeted approach to immunosuppressive therapy for uveitis than standard immunomodulatory drugs.

Compared with standard systemic immunosuppressive drugs, BRMs represent more specific, targeted therapies with the potential for fewer side effects and greater effectiveness.

In addition to the approved BRM, a number of biologics are being investigated as treatment for uveitis with some promising results.

Dr. Suhler cautioned, however, that early findings are not always confirmed in larger studies, and with some of the biologics there is a need for more long-term safety information.



Dr. Suhler

ON-LABEL OPTION

Adalimumab (Humira, AbbVie), an anti-tumor necrosis factor α (TNF- α) monoclonal antibody, was approved by the FDA for the treatment of adults with non-infectious intermediate, posterior, and panuveitis (NIIPP) in July 2016, based on the results of the multinational phase III VISUAL I and VISUAL II trials.

In October 2018, the indication was expanded to include children ages 2 and older based on results of the

SYCAMORE study that investigated adalimumab plus methotrexate for uveitis in patients with juvenile idiopathic arthritis.

VISUAL I enrolled patients with active uveitis despite systemic corticosteroid treatment and VISUAL II enrolled patients with corticosteroid-dependent, well-controlled disease. Treatment failure was analyzed as the primary endpoint in both trials. Compared with placebo, adalimumab reduced the risk of treatment failure by 50% in VISUAL I and by 43% in VISUAL II.

VISUAL III was an open-label extension study that enrolled patients from the pivotal trials described previously who either had completed these studies successfully over 18 months or who were discontinued after meeting predefined treatment failure criteria. Results from VISUAL III showed the previously successfully treated cohort had sustained-disease control while being maintained on subcutaneous adalimumab every other week while patients with active disease who started on adalimumab achieved rapid benefit despite tapering of their corticosteroid dose.

“This is a rare example of where the results of an open-label extension study were as compelling or maybe

even more compelling than the results of the preceding randomized trials,” Dr. Suhler said.

OFF-LABEL TNF- α BLOCKERS

Infliximab (Remicade, Janssen) is another anti-TNF- α treatment that has demonstrated efficacy in the treatment of NIIPP uveitis. Given as an intravenous infusion every 8 weeks after an initial loading phase, infliximab may be an attractive option for patients who are expected to be non-compliant with self-administered subcutaneous injections, Dr. Suhler said.

Limited data provide evidence that two other anti-TNF- α agents, certolizumab (Cimzia, UCB) and golimumab (Simponi, Janssen) are also effective treatment for NIIPP uveitis, in contradistinction to the anti-TNF- α fusion protein, etanercept (Enbrel, Amgen), which has been shown fairly clearly to not be effective in treatment of uveitis.

More convenient dosing is a feature of certolizumab and golimumab—both are administered monthly as a subcutaneous injection. Because pharmacokinetic data show low to negligible placental transfer of certolizumab, it is also considered as an attractive option for patients who are pregnant or wanting to become pregnant, Dr. Suhler said.

Discussing safety, Dr. Suhler noted that data from the rheumatology literature show treatment with anti-TNF- α agents may be associated with increased risks of malignancy and serious infections. The Systemic Immunosuppressive Therapy for Eye Diseases 1 (SITE-1) study also raised safety concerns, showing in-

creased cancer-specific and all-cause mortality.

New information from SITE-2, which was presented later on the same day, however, showed that with increased follow-up from SITE-1, there did not seem to be an increased risk of malignancy in uveitis patients treated with TNF-blockers. As a bottom line, the risk of losing sight from uncontrolled uveitis is greater than the risks associated with anti-TNF- α treatment.

“All immunosuppressive drugs carry risk, and while there may be a slightly increased arithmetic risk of malignancy or infection with the anti-TNF- α drugs, the overall population attributable risk for these events is low, especially in comparison to the risk of vision loss for patients with poorly treated NIIPP uveitis, which is not low,” Dr. Suhler said.

OTHER BRMS

Rituximab (Rituxan, Genentech/Roche) is a commercially available B-cell blocker indicated for treating several diseases that are associated with scleritis, including rheumatoid arthritis and granulomatosis with polyangiitis, and microscopic polyangiitis.

Dr. Suhler noted that it has also demonstrated efficacy for treatment of scleritis and orbital inflammation in case series from his own institution. In addition, rituximab is being used for treating vitreoretinal lymphoma and has demonstrated efficacy in limited series as treatment for uveitis and ocular cicatricial pemphigoid.

Tocilizumab (Actemra, Genentech/Roche), which blocks interleukin-6 (IL-6), has demonstrated efficacy in a case series of patients with juvenile idiopathic arthritis-associated uveitis,

and appears to have particular benefit for controlling uveitic macular edema. In the STOP-UVEITIS study, tocilizumab was modestly effective for treating uveitis-related vitreous haze.

“Tocilizumab is much more effective for treating macular edema than inflammatory disease, but it may be worth trying tocilizumab to control inflammation when macular edema is present or in any patient with significant macular edema that is refractory to other therapies,” he said.

Results are being awaited from an NEI-sponsored study investigating the IL-12/23 blocker, ustekinumab (Stelara, Janssen), as a treatment for NIIPP uveitis, and an industry-sponsored multicenter randomized clinical trial is also under way investigating filgotinib (Gilead Sciences), a janus kinase 1 (JAK) inhibitor.

“Filgotinib and other JAK inhibitors act at a very upstream point to block the transcription of pro-inflammatory cytokines and are also appealing because they can be given orally,” Dr. Suhler said. ■

ERIC B. SUHLER, MD, MPH

E: suhlere@ohsu.edu

This article was adapted from Dr. Suhler's presentation during Uveitis Subspecialty Day at the 2018 meeting of the American Academy of Ophthalmology. He is a consultant to, receives lecture fees, and/or receives grant support from AbbVie, Aldeyra, EyeGate, EyePoint, Gilead Sciences, and Santen, and received previous support relevant to this article from Centocor and Genentech.

Clearside receives notice of FDA acceptance of NDA filing for Xipere

CLEARSIDE Biomedical announced it received notification from the FDA that the agency has accepted for review the New Drug Application (NDA) for triamcinolone acetonide ophthalmic suspension (Xipere) for suprachoroidal injection for the treatment of macular edema associated with uveitis.

The FDA determined the application is sufficiently complete to permit a substantive review, said the company in a prepared statement.

The PDUFA (Prescription Drug User Fee Act) goal date has been assigned for Oct. 19, 2019. This date reflects a standard review period and is consistent with management's expectations for the 505(b)(2) filing.

“We are delighted with this positive news on our Xipere NDA,” said Daniel H. White, president and chief executive officer. “If Xipere is approved, Clearside will have the first therapy indicated for patients suffering from macular edema associated with uveitis.”

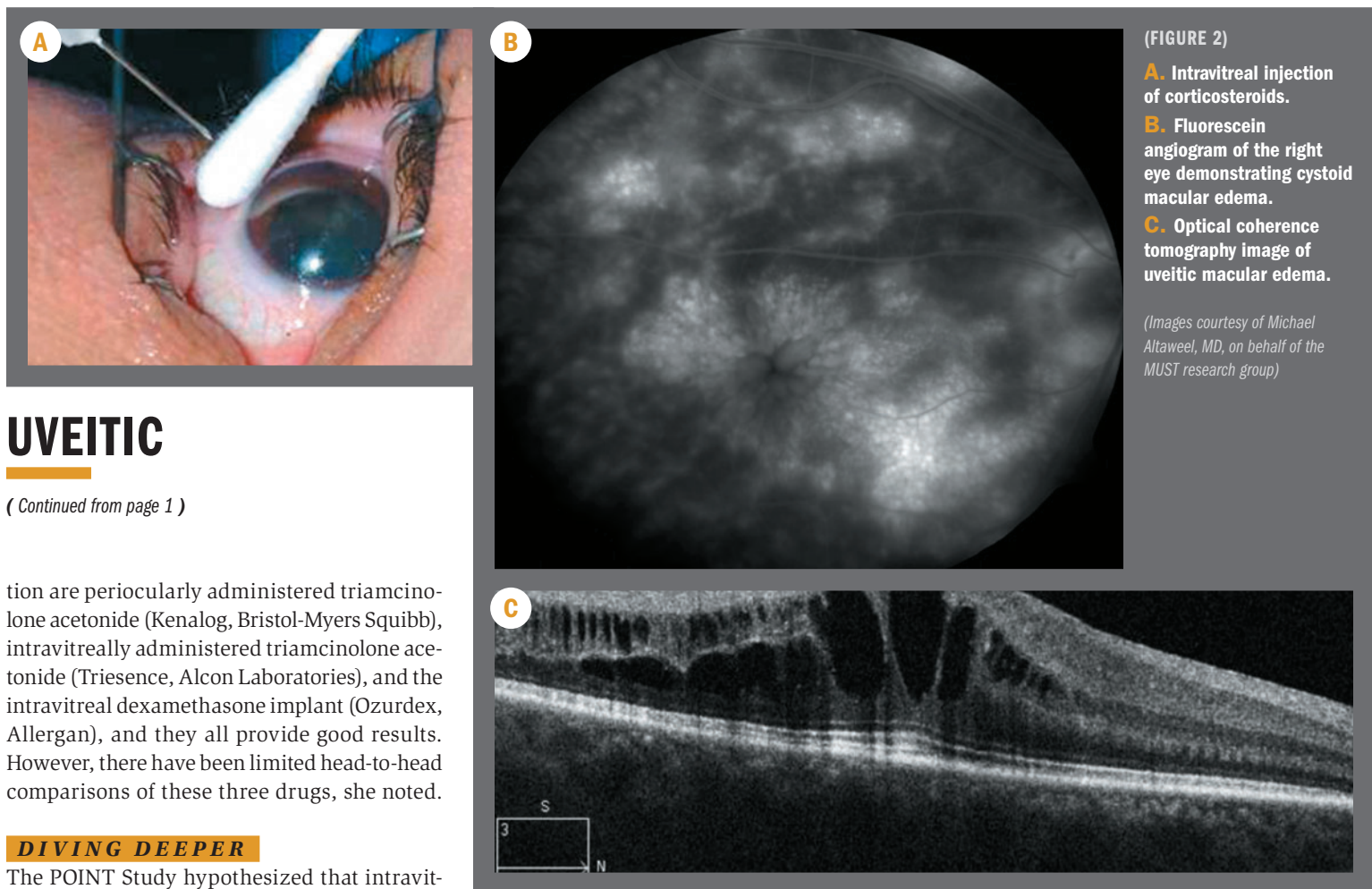
“Macular edema is the leading cause of vision loss, and even blindness, in uveitis patients, and we are now one step closer to treating this underserved patient population,” White added. “Over the last several months, our team has worked diligently to reach this milestone and we are now preparing to launch the product if approved.”

The NDA filing is supported by data from

the phase III PEACHTREE clinical trial that demonstrated significant and clinically meaningful improvement in vision for patients with macular edema associated with non-infectious uveitis, and that improvement was achieved across all anatomical locations of uveitis, said the company in the statement.

Also, in patients with active inflammation at baseline, resolution was achieved in more than two-thirds of those treated with Xipere across three commonly used measures of inflammation: vitreous haze, anterior chamber cells and anterior chamber flare, according to the company. ■

Special Report) THERAPEUTIC MANAGEMENT OF **UVEITIS & RETINA**



(FIGURE 2)

- A.** Intravitreal injection of corticosteroids.
B. Fluorescein angiogram of the right eye demonstrating cystoid macular edema.
C. Optical coherence tomography image of uveitic macular edema.

(Images courtesy of Michael Altaweel, MD, on behalf of the MUST research group)

UVEITIC

(Continued from page 1)

tion are periocularly administered triamcinolone acetonide (Kenalog, Bristol-Myers Squibb), intravitreally administered triamcinolone acetonide (Triesence, Alcon Laboratories), and the intravitreal dexamethasone implant (Ozurdex, Allergan), and they all provide good results. However, there have been limited head-to-head comparisons of these three drugs, she noted.

DIVING DEEPER

The POINT Study hypothesized that intravitreal triamcinolone and the intravitreal dexamethasone sustained-release implant would be better for treating uveitic macular edema than the periocularly administered triamcinolone, and the dexamethasone implant would not be inferior to intravitreal triamcinolone.

The study also hypothesized that the dexamethasone implant would be associated with a low rate of IOP elevations compared with intravitreal triamcinolone.

The 192 patients with uveitic macular edema in this multicenter trial were randomly assigned to one of three treatments:

- ▶ periocular triamcinolone 40 mg (74 eyes),
- ▶ intravitreal triamcinolone 4 mg (82 eyes), or
- ▶ the intravitreal dexamethasone implant 0.7 mg (79 eyes).

Patients underwent ophthalmic examinations with optical coherence tomography (OCT) testing at baseline and at 4, 8, 12, 20, and 24 weeks after the start of treatment. The investigators recently published their findings (*Ophthalmology*. 2019;126:283-295).

The primary study outcome compared the proportion of improvement of OCT central subfield thickness from baseline to the 8-week primary outcome visit.

Secondary outcomes included a greater than

20% improvement in and resolution of macular edema on OCT, best-corrected visual acuity (BCVA), and the IOP events over the 24-week study, according to Dr. Thorne.

At the primary outcome visit, the macular edema improved in all treatment groups. The injections of the two intravitreally administered treatments resulted in greater reductions ($p < 0.0001$) in uveitic macular edema at 8 weeks compared with the periocularly administered triamcinolone; no significant difference was seen between the two intravitreal treatments at 8 weeks.

The decreases in the macular edema obtained with intravitreal triamcinolone, intravitreal implant, and periocular triamcinolone were 39%, 46%, and 23%, respectively.

BCVA improved in all three groups, but the intravitreal drugs were superior to periocular therapy. Intravitreal triamcinolone and the

take-home

▶ **Intravitreal injections of triamcinolone acetonide and intravitreal dexamethasone implant achieve better results than periocular triamcinolone acetonide in patients with uveitic macular edema in a study.**

dexamethasone implant resulted in significant ($p < 0.004$) improvements in BCVA that were 5 letters greater than in the periocular drug group at the 8-week evaluation.

The risk of an IOP elevation was greater in the intravitreally injected groups when compared with the periocular group, but the occurrence of IOP elevations over 30 mm Hg were low for all three groups. The dexamethasone implant had risks of IOP elevation similar to intravitreal triamcinolone.

The authors concluded that intravitreal triamcinolone acetonide and the dexamethasone implant were superior to periocular triamcinolone for treating uveitic macular edema with modest increases in the risk of IOP elevation. This risk did not differ significantly between intravitreal treatments. ■



JENNIFER E. THORNE, MD, PHD

E: jthorne@jhmi.edu

This article was adapted from Dr. Thorne's presentation during Uveitis Subspecialty Day at the 2018 meeting of the American Academy of Ophthalmology. This study was supported by grants from National Eye Institute/National Institutes of Health and Allergan. Dr. Thorne is on the advisory boards for AbbVie, Clearside, and Santen, and is a consultant for Gilead and NightstarRx.

Adalimumab efficacious for uveitis regardless of disease duration

Quiescence, steroid-free quiescence achieved in VISUAL III trial

By **Lynda Charters**; Reviewed by **Jennifer E. Thorne, MD, PhD**

ADALIMUMAB (Humira, AbbVie) is safe and effective for treating non-infectious uveitis regardless of how long the patients have had the disease, according to Jennifer E. Thorne, MD, PhD.

The drug, which was tested in the VISUAL III trial, effectively increased the percentage of patients who achieved quiescence and steroid-free quiescence regardless of the disease duration upon entry into the study, said Dr. Thorne, MD, PhD, the Cross Family Professor of Ophthalmology, and chief, Division of Ocular Immunology, Wilmer Eye Institute, and professor of epidemiology, Johns Hopkins Bloomberg School of Public Health, Baltimore.



Dr. Thorne

The VISUAL III trial is an open-label extension study in which quiescence was defined as no active inflammatory lesions and an anterior chamber cell grade of 0.5+ or lower and a vitreous haze grade of 0.5+ or lower. Inflammatory lesions were defined as inflammatory chorioretinal and/or inflammatory retinal vascular lesions, Dr. Thorne noted.

In line with the improvements in uveitis, the mean logMAR BCVA also improved between weeks 0 and 78 weeks in the three patient subgroups.

The study endpoints were determination of the percentage of patients with quiescence and steroid-free quiescence, the mean daily systemic corticosteroid dose, the mean logarithm of the minimum angle of resolution (logMAR) best-corrected visual acuity (BCVA), and any

adverse events through week 78 of the study. The results were assessed in three subgroups based on the disease duration, i.e., less than 1 year, 1 year to less than 3 years, and 3 years or longer.

take-home

► **Adalimumab obtained good results in patients with non-infectious uveitis regardless of the length of time the patients had the disease.**

A total of 424 patients were enrolled in the study. The patients received a loading dose of 80 mg, followed by 40 mg of adalimumab every other week out to 78 weeks. When divided into the subgroups based on disease duration, 50 patients had uveitis for less than 1 year, 125 for from 1 year to less than 3 years, and 196 for 3 years or longer. The respective mean disease durations were 8.2 ± 2.7 , 22.2 ± 6.9 , and 102.5 ± 71.8 months, Dr. Thorne said.

The proportion of patients with disease quiescence improved over time regardless of the duration of the disease. At week 78, across the three disease duration subgroups, 85% or more of the patients had achieved quiescence.

In addition, the investigators saw numeric improvements in the percentages of patients who achieved steroid-free quiescence regardless of the disease duration. By week 78, across the three disease duration subgroups, 57% to 63% of patients had achieved quiescence without the need for daily corticosteroids.

OBSERVATIONS

The investigators also observed that reductions in the mean systemic corticosteroid daily dose were achieved regardless of the disease duration compared with baseline. The mean decreases were: 10.5 mg/day among patients with

uveitis for less than 1 year, 6.0 mg/day among patients with uveitis for from 1 year to less than 3 years, and 7.0 mg/day among patients with uveitis for 3 years or longer.

In line with the improvements in uveitis, the mean logMAR BCVA also improved be-

OT OphthalmologyTimes.com
Online Exclusive

PODCAST: ADVANCES IN FLOATER TREATMENT

AFTER SPENDING years encouraging and helping train colleagues to treat floaters, Christopher F. Wood, MD, is confident that the technologies available today will allow ophthalmologists to safely popularize the procedure and expand access to many more patients.

Go to OphthalmologyTimes.com/EyePod

tween weeks 0 and 78 weeks in the three patient subgroups. The mean logMAR BCVA at week 78 was 0.05, 0.06, and 0.15, respectively.

No new safety signals were identified, and the safety profile was consistent with the known safety profile across the approved indications for adalimumab. More adverse events occurred among the patients with uveitis for less than 1 year that possibly were related to higher rates of corticosteroid use in that subgroup. When analyzed by the corticosteroid dose, patients taking more than 7.5 mg daily had more adverse events than patients taking 7.5 mg daily or less in each disease duration subgroup.

Dr. Thorne concluded, "Analyses from the VISUAL III trial of patients with non-infectious uveitis treated with adalimumab demonstrated improved efficacy outcomes through weeks 0 to 78 of the study, regardless of the disease duration of uveitis, for the following endpoints: the proportion of patients with quiescence and steroid-free quiescence, the mean daily corticosteroid dose, and BCVA." ■

JENNIFER E. THORNE, MD, PHD

E: jthorne@jhmi.edu

This article was adapted from Dr. Thorne's presentation at the 2018 meeting of the American Academy of Ophthalmology. Dr. Thorne is on the advisory boards for AbbVie, Clearside, and Santen, and is a consultant for Gilead, and NightStarRx. She receives grants funding from the NEI/NIH and Allergan.

Sustained-release corticosteroid expands armamentarium for uveitis

FA implant effective in lowering recurrence rates through available 6, 12 months of follow-up

By Cheryl Guttman Krader; Reviewed by David Callanan, MD

FOLLOWING THE FDA approval of the fluocinolone acetonide (FA) 0.18 mg intravitreal implant (Yutiq, EyePoint Pharmaceuticals) for the treatment of chronic non-infectious uveitis affecting the posterior segment of the eye in October 2018, the product was launched for commercial use in February 2019.



Dr. Callanan

According to uveitis specialist, David Callanan, MD, access to the sustained-release corticosteroid implant is a welcome development because it

provides clinicians with another great tool for treating appropriately selected patients affected by this sight-threatening disease.

“Every uveitis patient with posterior uveitis is unique, and individuals may respond differently to different medications,” said Dr. Callanan, partner, Texas Retina Associates, and clinical professor of ophthalmology, University of Texas Southwestern Medical School, Dallas. “Locally administered corticosteroids, however, are generally very effective, and the ability to treat locally is important, especially for avoiding exposure to toxicities of systemic medications in patients who do not have associated extraocular findings or for those whose uveitis is not responding adequately to systemic immunomodulatory therapy.”

‘Every uveitis patient with posterior uveitis is unique, and individuals may respond differently to different medications.’ — David Callanan, MD

“Phase III study results demonstrate that the new FA implant was effective for lowering recurrence rates through the available 6 and 12 months of follow-up, and the safety data on IOP elevation are encouraging so far,” he said.

(FIGURE 1) The new fluocinolone acetonide (FA) 0.18 mg intravitreal implant uses a non-bioerodible, micro-insert platform that is designed to release a daily FA dose of 0.25 mcg over 3 years. David Callanan, MD, noted the minute size of the implant probably explains why the majority of patients do not seem to be aware of its presence in the eye.

(Image courtesy of EyePoint Pharmaceuticals)



“The trials are ongoing, and we look forward to longer-term findings.”

The new FA implant uses a non-bioerodible, micro-insert platform that is designed to release a daily FA dose of 0.25 mcg over 3 years.

The micro-insert is injected into the vitreous through the pars plana using a pre-loaded sterile applicator fitted with a 25-gauge needle. The injection is done in an in-office procedure akin to that used for intravitreal injections of anti-VEGF medications or dexamethasone 0.7 mg intravitreal implant (Ozurdex, Allergan).

“Unlike the previously available FA 0.59 mg implant (Retisert, Bausch + Lomb), intravitreal placement of the new FA product does not have to be done in the operating room,” Dr. Callanan said. “Compared with the dexamethasone

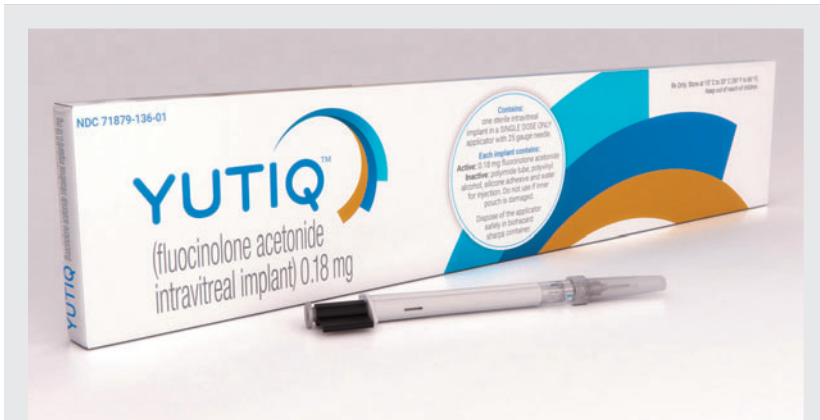implant, the new FA implant is longer acting and therefore holds promise for maintaining remission with fewer re-injections.”

“Although the benefit of the dexamethasone implant (Ozurdex, Allergan) persisted for about 6 months in its pivotal clinical trial, clinical experience shows that efficacy can be lost after 3 months in quite a few patients,” he said. “Our aim in treating uveitis is to maintain quiescence and eliminate repeated flares that can lead to permanent tissue damage, and achieving that goal with the dexamethasone implant may carry a relatively high injection burden for some patients.”

CLINICAL TRIAL RESULTS

In two phase III trials, patients with non-infectious posterior uveitis were randomly assigned to treatment with the FA 0.18 mg implant or sham injection. Eligible patients had been affected by posterior uveitis for at least 1 year and experienced at least 2 separate re-

Special Report) THERAPEUTIC MANAGEMENT OF **UVEITIS & RETINA**



(FIGURE 2) The micro-insert is injected into the vitreous through the pars plana using a preloaded sterile applicator fitted with a 25-gauge needle. The injection is done in an in-office procedure. (Image courtesy of EyePoint Pharmaceuticals)

currences requiring treatment with systemic medication (corticosteroid or immunosuppressive medications) or local corticosteroid injections (intraocular or periocular) or had received systemic therapy for at least 3 months

or at least 2 local corticosteroid injections during the previous 12 months.

The rate of recurrent uveitis flares at month 6 was analyzed as the primary endpoint and was significantly lower ($p < 0.01$) in both studies in the FA group compared with the control group (18.4% versus 78.6% and 21.8% versus 53.8%). A statistically significant difference ($p < 0.01$) in the recurrence rate favoring the FA implant group over the control group was also achieved at month 12 (27.6% versus 85.7% and 32.7% versus 59.6%) ($p < 0.01$ for all comparisons of FA versus sham).

“Based on the statistical plan that was designed for trial robustness, patients who missed the 6-month follow-up visit were counted as having a recurrence, and for that reason, the recurrence rates in the FA group may be artificially high,” Dr. Callanan said.

The safety review for data collected through 12 months showed that the mean IOP increase was 1.3 mm Hg in the FA implant group and 0.2 mm Hg for the controls in one study and 2.0 mm Hg for the FA implant group and

0.0 mm Hg in the control group in the other trial. In a pooled analysis, the percentages of patients requiring any IOP-lowering medication and undergoing surgery for elevated IOP were similar in the FA implant and control

take-home

► A new fluocinolone acetonide intravitreal implant (Yutiq, EyePoint Pharmaceuticals) that is expected to release a fixed-corticosteroid dose for 3 years is now commercially available for the treatment of chronic non-infectious uveitis affecting the posterior segment of the eye.

groups. Rates of cataract surgery in the two studies were 33.3% and 18.0% in the FA implant group and 4.8 and 8.6% for the control group.

“The prescribing information for the FA 0.59 mg implant (Retisert) notes that based on clinical trial data, about 77% of patients will require IOP-lowering medications and 37% of patients will require glaucoma filtering surgery within 3 years after implantation,” he said.

Early data with the new FA implant suggest IOP elevation may be a less significant issue. A possible explanation for the difference may be that the older FA implant is surgically sewn into the pars plana close to the crystalline lens and ciliary processes. The new FA implant (Yutiq) is also a lower dose than the previous 0.59 mg implant (Retisert), he added.

Dr. Callanan noted the minute size of the implant probably explains why the majority of patients do not seem to be aware of its presence in the eye.

PATIENT SELECTION

Dr. Callanan said that the ideal candidate for treatment with the new FA

implant is a pseudophakic patient with chronic non-infectious posterior uveitis who has demonstrated a therapeutic response to prior local corticosteroid treatment without significant IOP. ■

DAVID CALLANAN, MD

E: dcallanan@texasretina.com

Dr. Callanan is an investigator in one of the phase III

FA 0.18 mg implant clinical trials and is a consultant to EyePoint Pharmaceuticals.

Digital and 4K Video Imaging Solutions for Slit Lamps and Surgical Microscopes

Universal Digital SLR Camera Adaptor

Universal Smart Phone Adaptor for Slit Lamp Imaging

Sample Images

Ikegami 4K Video for Surgical Microscopes & Slit Lamps

Made in USA

TTI Medical

Transamerican Technologies International
 Phone: +1-925-553-7828
 email: info@ttimedical.com
www.ttimedical.com

Tocilizumab effective for managing posterior segment inflammation

Improvement in visual acuity, central retinal thickness, vitreous haze reported at 6 months

By **Nancy Groves**; Reviewed by **Muhammad Hassan, MD**; **Mohammad Ali Sadiq, MD**; **Yasir J. Sepah, MBBS**; and **Quan Dong Nguyen, MD, MSc**

REPEATED intravenous infusions of tocilizumab (Actemra, Genentech), an investigational systemic therapy for non-infectious uveitis of the posterior segment, are well tolerated and effective in improving visual acuity and reducing vitreous haze and retinal edema. Further analysis of data from the STOP-Uveitis Study

also indicates that tocilizumab is effective in improving posterior segment inflammation in eyes with non-infectious intermediate, posterior, and panuveitis, according to Muhammad Hassan, MD, chief clinical research fellow, Byers Eye Institute, Stanford University, Stanford, CA.

He highlighted 6-month outcomes from the STOP-Uveitis Study, a phase I/II trial conducted at five clinical sites in the United States. In this randomized, open-label safety, tolerability, and efficacy study, 37 patients were assigned 1:1 to receive intravitreal infusions of 4 mg/kg or 8 mg/kg of tocilizumab, an anti-interleukin-6 antibody. Patients received monthly infusions from baseline through month 5, then as needed starting at month 6.

Tocilizumab is approved for the treatment of rheumatoid arthritis, giant cell arteritis, systemic juvenile idiopathic arthritis, polyarticular juvenile idiopathic arthritis, and cytokine release syndrome. In addition, tocilizumab has demonstrated safety and efficacy in several small, single-center studies of cases with non-infectious uveitis and uveitic macular edema refractory to other immunosuppressive therapies.

Efficacy outcomes were mean change in best-corrected visual acuity (BCVA), central retinal thickness (CRT), and vitreous haze. Six-month data from the combined groups showed a statistically significant ($p < 0.01$) mean improvement in BCVA of 8.22 ETDRS letters, from a mean of 37.78 letters at baseline to 46.0 at the 6-month endpoint. Both study groups demonstrated a statistically significant change from

baseline of 10.94 letters for the low-dose group and 5.5 letters for the high-dose group.

The mean change in CRT for the combined groups was also statistically significant ($p < 0.01$), 83.89 μm at 6 months (358.25 μm at baseline to 274.37 μm at the endpoint). The changes for the 4 mg/kg and 8 mg/kg groups were 131.5 μm and 38.91 μm , respectively.

The haze analysis scores at month 6 showed a decrease of 1 step or more in 77.4% ($n = 24$) of patients in the combined treatment groups and a decrease of 2-steps or more in 32.2% ($n = 10$). Out of the 37 patients, only 23 patients had the potential for 2-step improvement, and among these 43% (10 patients) demonstrated a 2-step improvement, he said.

There was no change in 7 patients (22.6%), and haze worsened in 1 patient.

PRIMARY OUTCOMES

The primary outcomes of the STOP-Uveitis study were published in the *American Journal of Ophthalmology* in late 2017. However, because 14 of the patients in the study did not have the potential for 2-step improvement in vitreous haze, the investigators wanted to analyze the effect of tocilizumab on posterior segment inflammatory outcomes using a semi-quantitative fluorescein angiography (FA) scoring system. This system was developed by the Angiography Scoring for Uveitis Working Group in 2010 to as-

sist in the follow up of progression and monitoring treatment response in uveitic patients.

A maximum score has been derived for each of 9 angiographic signs with a possible total score of 40. The components are: optic disc hyperfluorescence, macular edema, retinal vascular staining/leakage, capillary leakage, retinal capillary nonperfusion, neovascularization of the optic disc, neovascularization elsewhere, pinpoint leaks, and retinal staining/pooling.

This system was used to analyze FA images and calculate inflammatory scores at baseline and month 6 visits in the STOP-Uveitis Study;

two trained graders from the Ocular Imaging Research and Reading Center (Sunnyvale, CA) analyzed all images. Thirty eyes were eligible for analysis and 7 were excluded.

Both dosing groups showed a statistically significant reduction in FA inflammatory scores from baseline to month 6 ($p < 0.05$). The difference in mean reduction between the 2 dose groups was not statistically significant. Overall, the mean score at baseline was 5.37 compared to 2.71 at month 6 ($p < 0.002$). For group 1 ($n = 15$) receiving the 4 mg/kg dose, the score improved from 6.33 to 3.22 ($p < 0.026$); for the 8 mg/kg group ($n = 15$), the score improved from 4.35 to 2.18 ($p < 0.033$). The difference in mean reduction between the two groups was not statistically significant.

The study suggested that repeated intravenous infusions of tocilizumab are well tolerated and effective in improving visual acuity, reducing haze and retinal edema and improving inflammation, but further monitoring of patients is needed to assess the long-term benefits of tocilizumab for the treatment of non-infectious uveitis and uveitic macular edema.

Based on the limited data from the study, the higher dose does not seem to provide any additional benefit over the lower dose and that further studies with IL-6 inhibition are needed to elucidate the role of IL-6 inhibitors in the armamentarium for uveitis therapy. ■



Dr. Hassan

take-home

► **The STOP-Uveitis Study has shown that intravenous infusions of the humanized monoclonal antibody tocilizumab are effective as a novel therapeutic management approach for non-infectious uveitis.**

MUHAMMAD HASSAN, MD

P: 402/953-6773 E: hassanm@stanford.edu

This article was adapted from Dr. Hassan's presentation during the 2018 meeting of the American Academy of Ophthalmology. Dr. Hassan did not report any relevant financial disclosures.

MOHAMMAD ALI SADIQ, MD

Dr. Sadiq is a clinical research fellow in the Department of Ophthalmology at Stanford University. Dr. Sadiq did not report any relevant financial disclosures.

YASIR J. SEPAH, MBBS

Dr. Sepah is a senior research scientist at Stanford University. He did not report any relevant financial disclosures.

QUAN DONG NGUYEN, MD, MSc

E: ndquan@stanford.edu

Dr. Nguyen is a professor at the Byers Eye Institute, Stanford University. Dr. Nguyen did not report any relevant financial disclosures.

Ongoing study evaluates sirolimus as therapeutic option for uveitis

Inhibition plays role in autoimmune-based inflammation; has unique mechanism of action

By Cheryl Guttman Krader; Reviewed by Steven Yeh, MD

THE PHASE III LUMINA study is under way assessing the efficacy and safety of intravitreal sirolimus 440 µg (Opsiria, Santen) administered every 2 months for the treatment of active, non-infectious uveitis of the posterior segment, according to Steven Yeh, MD.



Dr. Yeh

Launched in November 2018, the multicenter study plans to enroll 200 patients who are being randomly assigned into three arms (2:2:1) to receive:

- ▣ sirolimus 440 µg (experimental test arm),
- ▣ a sham procedure (control arm), or
- ▣ sirolimus at an undisclosed, fixed dose (within the range of 44 to 880 µg) (dummy arm) every 2 months.

After an initial 6-month, double-masked, controlled period, LUMINA will continue with a 6-month, single-arm, open-label period to allow further evaluation of the efficacy and safety of intravitreal sirolimus 440 µg every 2 months for a longer duration than is appropriate for treatment with placebo or sham injection, explained Dr. Yeh, the M. Louise Simpson Associate Professor of Ophthalmology; director of the Uveitis Service, Emory Eye Center, Atlanta, and an investigator in LUMINA.

Elimination of vitreous haze (VH; VH score of 0) at month 3 is being analyzed as the pri-

mary outcome measure. Key secondary outcome measures include VH score of 0 or 0.5+ at month 3 and month 5 and percentage of patients with corticosteroid tapering success with resolution (VH score of 0) at month 3 and month 5.

UNMET NEED

Dr. Yeh is pleased Santen is continuing to pursue the development of sirolimus for non-infectious posterior uveitis given the unmet need for local therapy that averts corticosteroid-related side effects.

“We have a number of medications that can be used to treat posterior uveitis either systemically or locally, including corticosteroids and other immunosuppressive therapies, but they all have varying degrees of side effects that can pose limitations to their use,” he said.

Sirolimus inhibits the activity of the mammalian target of rapamycin (mTOR) that plays a critical role in autoimmune-based inflammation, and thus has a unique mechanism of action for controlling uveitis, he noted.

“It demonstrated promising efficacy signals in the phase III SAKURA program with good tolerability,” Dr. Yeh said. “It also had an acceptable side effect profile as it caused minimal elevation of IOP and cataract development.”

LUMINA is an important trial because it is continuing to evaluate the evidence for the role of sirolimus, and it can potentially give us another medication to use for this challenging disease process, he added.

The LUMINA protocol is designed to study control of active disease. In contrast to the SAKURA program protocol that originally included two experimental test arms evaluating sirolimus doses of 440 and 880 µg and used sirolimus 44 µg for the control, LUMINA is evaluating only the 440 µg dose, and control patients are receiving a sham injection. “In the SAKURA program, 440 µg sirolimus had the most favorable benefit:risk profile among the three doses studied,” he said.

The dummy arm in LUMINA is interesting from a study design perspective and can provide valuable information. The undisclosed, fixed dose (within the range of 44 µg to 880 µg) will be administered to patients in this arm and will be included in the study to help ensure masking of treatment assignments, he noted.

The anticipated completion date of LUMINA is 2021. Thirty-five study sites are participating. ■

take-home

▸ An ongoing phase III, sham-controlled study is investigating intravitreal sirolimus 440 µg (Opsiria, Santen) for the treatment of active, non-infectious uveitis of the posterior segment.

STEVEN YEH, MD

E: steven.yeh@gmail.com

Dr. Yeh is a consultant to Santen and Clearside Biomedical.

Adalimumab approved by Health Canada for pediatric uveitis

ABBVIE announced that Health Canada has approved adalimumab (Humira) for the treatment of chronic non-infectious anterior uveitis in pediatric patients from two years of age who have had an inadequate response to or are intolerant to conventional therapy, or in whom conventional therapy is inappropriate.

Adalimumab is now the only approved biologic treatment option for chronic non-infectious

anterior uveitis in children aged two years and older in Canada, said the company.

“This approval marks an important milestone for pediatric uveitis patients and their caregivers who, up until this point, had no biologic treatment options available to them,” said Stéphane Lassignardie, general manager of AbbVie Canada. “This label expansion further demonstrates AbbVie’s dedication to ad-

ressing the unmet medical needs for both adult and pediatric patients living with serious immune-mediated inflammatory diseases.”

The approval is based on results from the SYCAMORE trial, which showed that adalimumab combined with methotrexate significantly delayed the time to treatment failure compared with methotrexate plus placebo in children with active JIA-associated uveitis. ■

IL-6 inhibition shows promise as treatment for non-infectious uveitis

Sarilumab may be effective in controlling inflammation, improving macular edema

By Cheryl Guttman Krader

RESULTS FROM SATURN, an exploratory phase II study, suggest that sarilumab (Kevzara, Sanofi/Regeneron)—a human monoclonal antibody directed against the alpha subunit of the interleukin-6 (IL-6) receptor complex—may be an effective treatment for controlling inflammation, improving vision, and resolving macular edema in patients with severe non-infectious uveitis involving the posterior segment, according to Quan Dong Nguyen, MD, MSc.

“Based on the findings from the phase II clinical trial, further studies are indicated to confirm the therapeutic role of sarilumab and IL-6 inhibition in the management of uveitis,” said Dr. Nguyen, professor of ophthalmology, Byers Eye Institute, Spencer Center for Vision Research, Stanford University, Palo Alto, CA.

THERAPEUTIC INTEREST

Outcomes from SATURN were published online in October 2018 [Heissigerová J, et al. *Ophthalmology*. 2018 Oct 11. Epub ahead of print]

Interest in IL-6 inhibition as treatment for non-infectious uveitis is based on several lines of evidence. IL-6 is known to cause ocular inflammation.

In addition, this cytokine and/or its soluble receptor have been detected in the vitreous and aqueous humors of patients with active intermediate or posterior uveitis, and in an animal model, treatment with an anti-IL-6 antibody was effective for suppressing the development of experimental autoimmune uveoretinitis.

In 2011, an initial clinical publication described efficacy of IL-6 inhibition with tocilizumab (Actemra, Genentech) in two patients with uveitis that was refractory to anti-TNF-alpha therapy, and subsequently, additional papers described positive data from retrospective cohort studies.

STUDY DESIGN

The SATURN study investigating sarilumab was an international, multicenter study that randomly assigned 58 patients 2:1 to subcutaneous treatment with sarilumab 200 mg every 2 weeks or placebo.

Eligible patients had to be receiving a stable dose of systemic steroids ≥ 15 mg/day prednisone equivalent alone or in combination with methotrexate ≤ 25 mg/week.

The primary endpoint that evaluated a 2-step reduction in vitreous haze (VH) score or a steroid-sparing benefit (dose reduction to < 10 mg prednisone equivalent) was analyzed at week 16. In an open-label extension phase continuing to week 52, patients originally randomly assigned to placebo were eligible to receive rescue therapy with sarilumab.

Dr. Nguyen indicated that the demographics characteristics of the enrolled patients were consistent with a typical uveitis population and balanced between the two study groups.

Patients had a mean age of 40 years and there were more females than males. Mean duration of uveitis activity was almost 4 years.

At baseline, 60% of patients had a VH score ≥ 2 , and the mean VH score for the entire population was 2.2.

Mean baseline best-corrected visual acuity (BCVA) was 72 letters, mean central retinal thickness (CRT) was 327 μm , and about half of patients had a baseline CRT ≥ 300 μm .

PRIMARY ENDPOINT ANALYSIS

Analysis of the week 16 data showed that the proportion of patients achieving the primary endpoint was numerically higher in the sarilumab arm compared with the placebo arm whether the VH assessment was done by the investigator or the reading center.

Secondary efficacy analysis showed that BCVA had improved from baseline in both study groups at week 16, but the mean improvement was more than 2-fold greater in the sarilumab arm compared with the control group. A difference favoring sarilumab was maintained at week 52.

Subgroup analyses were also performed that

included patients with a thicker retina at baseline (CRT ≥ 300 μm).

Among these patients who were also likely to have poorer baseline BCVA, treatment with sarilumab was associated with an even greater benefit at week 16 and further improvement at week 52, according to Dr. Nguyen.

CRT decreased by almost 50 μm at week 16 in sarilumab-treated eyes and by about 70 μm at week 52, but it was relatively unchanged in the control group throughout the 52 weeks of follow-up.

Again, the benefit of sarilumab was magnified in the subgroup analysis of eyes with a baseline CRT ≥ 300 μm .

The safety review of serious adverse events during the 52-week study showed that sarilumab treatment was associated with one case of marginalized neutropenia (2.6%).

“Marginalized neutropenia is a well-known adverse event associated with IL-6 inhibition,” Dr. Nguyen said. “In this condition, the neutrophils do not necessarily disappear from the body and they often shift back into the circulation after the medication is stopped.”

Results from a 6-month prospective study investigating tocilizumab for the treatment of uveitis also support benefit for IL-6 inhibition Sepah YJ, et al. *Am J Ophthalmol*. 2017;183:71-80.]. The data from the trial, STOP-UVEITIS, showed benefits for improvements in vitreous haze, BCVA, and macular edema. ■

take-home

► In a placebo-controlled phase II study of patients with severe non-infectious uveitis involving the posterior segment, subcutaneous sarilumab (Kevzara, Sanofi/Regeneron) demonstrated promising therapeutic activity.

QUAN DONG NGUYEN, MD, MSC

E: ndquan@stanford.edu

This article was adapted from Dr. Nguyen's presentation at the 2018 meeting of the American Academy of Ophthalmology. Dr. Nguyen serves on the Scientific Advisory Board for and receives research grant support from Regeneron Pharmaceuticals. He is a scientific advisor to and/or receives grant support from other companies marketing or developing treatments for uveitis.

Vision-screening tools aid children's needs worldwide

Novel technologies help with diagnosis in manner that is practical, adaptable to settings

By Robert W. Arnold, MD, FAAP; Special to Ophthalmology Times

In U.S. pediatricians' offices and clinics, children can receive state-of-the-art, age-appropriate amblyopia vision screening. This starts with specific instrument-based estimation of amblyopia risk factors and ends with sensitive monocular visual acuity screening. Insurance plans typically cover these tests. Children from economically depressed and politically oppressed regions of the world also deserve screening to prevent treatable blindness. By implementing emerging technology, vision-screening benefits can be offered to all children.

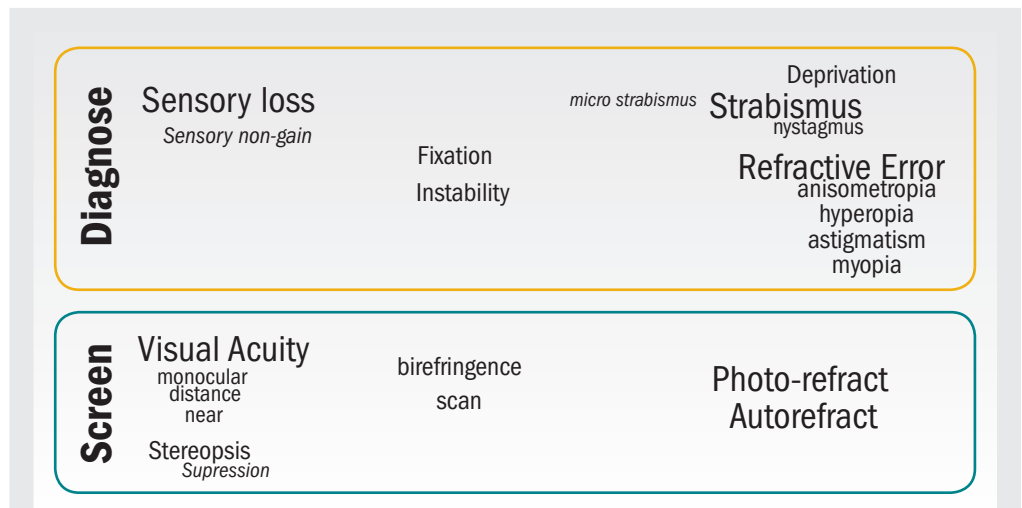
The World Health Organization (WHO) has published guidelines for many types of health screenings (Table 1).¹ Amblyopia, the most common form of childhood vision impairment due to deficient brain learning of vision, fits the guidelines.² Vision screening, of course, must be balanced with other high-priority health concerns in a given region. Screening for amblyopia must also be matched with a local ability to provide spectacles, patches, and other treatments.

TOOLS FOR MEDICAL MISSIONS

Advances have been made in tools that aid in amblyopia detection. This new technology is particularly helpful in developing countries.

Photoscreening analyzes the pupillary red reflex produced by a near co-axial flash and lens. If both eyes are aligned on a camera lens with perfect focus, the pupil will be filled with a uniform red image in both eyes. If the eyes are defocused, a crescent of light appears in the pupil with the extent of encroachment related to the amount of refractive error. Asymmetric red reflex can also be produced by strabismus.

Refractive errors, particularly anisometropia and high hyperopia, are amblyopia risk factors that are not apparent to the pediatrician (Figure 1). These vision disorders can be detected with photoscreening; early treatment with spectacles can profoundly reduce amblyopia.³



(FIGURE 1) Amblyopia diagnosis and screening. (Table courtesy of Robert W. Arnold, MD, FAAP)

Table 1: World Health Organization (WHO) health screening guidelines

1	Important health problem	Amblyopia
2	Accepted treatment for recognized disease	Early sturdy spectacles
3	Facilities for diagnosis and treatment	Child friendly skiascopy
4	Suitable latent and symptomatic stage	First decade
5	Suitable test or examination	Photoscreen then PDI Check
6	Test acceptable to population	Quick and fun
7	Natural history of condition understood	
8	Agreed on policy on whom to treat	
9	Cost of finding economically balanced with overall health	
10	Case finding should be continuous process	AAP guidelines

Today's photoscreeners implement multiple, sequential radial infrared flashes, with the original infrared photoscreener produced by the Ger-

man company, Plusoptix. These photoscreeners have proven to be accurate, supported by

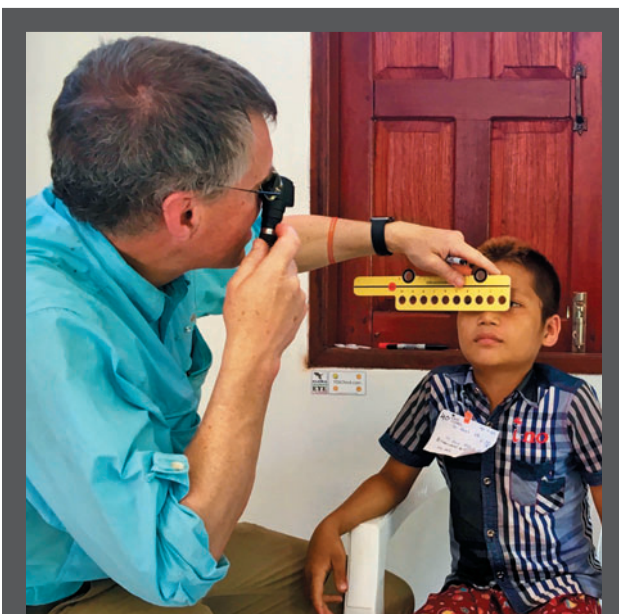Continues on page 26 : Photoscreeners



(FIGURE 2) Plusoptix photoscreener in war zone in Burma.
(All images courtesy of Robert W. Arnold, MD, FAAP)



(FIGURE 3) A PDI check near-vision game.



(FIGURE 4) The school bus accommodation-relaxing skiascopy is child-friendly and easy to use.

PHOTOSCREENERS

(Continued from page 25)

peer-reviewed studies. Screening devices are particularly useful worldwide (Figure 2), in part because they implement readily available AA batteries and easily adjustable instrument referral criteria.

Criteria can be highly sensitive in regions where follow-up exams are simple and affordable.

Referral criteria can also be adjusted to be more specific; therefore, reducing referral rate and the number of false positive referrals.

RECOMMENDATIONS

The American Academy of Pediatrics recommends a series of age-appropriate vision screenings during a child's first decade—the time when amblyopia occurs.⁴

Newborns should receive pupillary red reflex testing to look for congenital cataracts. Infants also should have fixation and cover testing to identify infantile esotropia. Starting at 12 months through kindergarten, specific photoscreening is quick and effective for detecting amblyopic risk factors.

After kindergarten, visual acuity screening is effective and can be a sensitive test if monocular acuity is assured. For distance acuity charts, monocular acuity is best assured with an occlusion patch.

Photoscreening with a Plusoptix device can be performed in less than 30 seconds per patient—which pediatric nurses and community screeners love. (The measurement itself takes less than a second.) Typical threshold monocular acuity screening takes more than 5 minutes especially in younger children.

Slow acuity screening is discouraging for busy pediatric offices or school screenings; a faster and more fun form of monocular acuity screening is warranted.

NOTHING WRONG WITH HAVING FUN

The Nintendo 3DS video game console has an autostereoscopic parallax barrier screen. PDI Check is a vision-screening game developed for the system allowing monocular acuity screening without occlusive patches and stereo screening without goggles (Figure 3).

PDI check can screen monocular acu-

ity, stereo, and color in about 100 seconds. Conventional patched acuity, plus booklet stereo and color testing takes about 4 minutes.

Once children are referred from vision screening, their refraction must be measured to determine appropriate amblyopia therapy usually involving sturdy spectacles. Accurately estimating hyperopia and astigmatism can be daunting in young and/or developmentally delayed children.

Another new tool, marketed by Eye Care and Cure, consists of a horizontally oriented convex skiascopy rack resembling a child-friendly school bus (Figure 4). By holding a higher plus lens over the non-retinoscoped eye, fogging allows accommodation almost as relaxed as that of cycloplegia.

CONCLUSION

Children everywhere should have appropriate screening tests. Pediatricians want valid tests with sufficient sensitivity and specificity. The screening test also should be acceptable to the population—tests that take a long time and are not child-friendly are much less acceptable.

New technology devices help in the diagnosis of vision disorders in a child-friendly manner that is not only practical but adaptable to various settings. ■

References

1. Wilson J, Junger G. Principles and practice of screening for disease. In: Public Health paper No. 34. Geneva: World Health Organization; 1968. <http://www.who.int/iris/handle/10665/37650>
2. Arnold RW. Towards worldwide amblyopia elimination- vision screening. *US Ophthalmic Review and European Ophthalmic Review*. 2009;2(1):91-98. doi: <http://doi.org/10.17925/EOR.2009.02.01.91>
3. Kirk VG, Clausen MM, Armitage MD, Arnold RW. Preverbal photoscreening for amblyogenic factors and outcomes in amblyopia treatment: early objective screening and visual acuities. *Arch Ophthalmol*. 2008;126:489-492.
4. Donahue S, Baker C. Visual system assessment in infants, children, and young adults by pediatricians. *Pediatrics*. 2016;137. <http://pediatrics.aappublications.org/content/pediatrics/137/1/e20153596.full.pdf>.



ROBERT W. ARNOLD, MD, FAAP

P: 907/561-1917 E: eyedoc@alaska.net
Dr. Arnold is a specialist in pediatric ophthalmology and strabismus. He is in practice at Alaska Children's Eye and

Strabismus in Anchorage, AK. He did not indicate any relevant financial disclosures.

Read-through, gene therapies for LCA showing promise

Group of researchers aim to validate both approaches in proof-of-concept study

By **Michelle Dalton, ELS**; Reviewed by **Bikash Pattnaik, PhD**

Genetic abnormalities on the *KCNJ13* gene are known to cause Leber's congenital amaurosis (LCA16). This particular gene encodes the Kir7.1 protein. A proof-of-concept study¹ has shown read-through therapy and gene augmentation can each rescue Kir7.1 channel function in induced pluripotent stem cell (iPSC)-retinal pigment epithelial (RPE) cells derived from affected individuals.

Though gene therapy is, itself, a simple concept, over- and under-expression can have negative effects, which only further emphasizes the need for optimum dosages.

"Our cell model showed that both treatments can restore the retinal cells to proper function," said principal investigator Bikash Pattnaik, PhD, assistant professor in the departments of pediatrics and ophthalmology and visual sciences, University of Wisconsin (UW)-Madison. "This gives us hope for the value of precision medicine."

LCA is a rare disorder—it affects 2 to 3 children per 100,000. Mutations in both photoreceptors and the RPE can cause LCA, Dr. Pattnaik said.

A mutated *KCNJ13* gene directly impacts the ability of the ion channel to function properly, thereby inhibiting the ability of the photoreceptor cells to encode visual stimuli.

"We started this research to determine how the RPE gene defect causes blindness," Dr. Pattnaik said. "This is a monogenic disease—meaning there is only one gene defect. Second, *KCNJ13* is an ion channel, which means for it to function you need the protein component."

Because of how proteins work, developing (or researching) gene therapy on ion channels is more difficult, he said, because of the lack of or low level of expression.

"Our study demonstrates stem cell technology can be used to overcome those barriers and analyze the pathophysiology of LCA16," he said.

STUDY DETAILS

The UW group first created a "disease in the dish" model to test two possible gene therapy approaches to reverse the damaged *KCNJ13* gene. In the first approach, skin cells were removed from two people in the same family (one with LCA, the other with no symptoms but one copy of the mutation). The skin cells were "re-engineered" back to an undifferentiated state and analyzed. Both types of cells appeared normal in structure.

But, when they matured, the cells from the LCA-affected person lacked the expression of the protein needed for the ion channel to develop and function. The team then tried to "rescue" the deficient ion channel through an approach known as "read-through therapy."

When the group was creating patient-derived iPSC cells, "we hoped that would address the question about what the protein was doing, what the ion channel was doing in these cells," he said. "We wanted to know if this was the only defect, or if there could be something else. That's where this became interesting."

The group used a lentivirus to try to re-establish a proper ion channel. Lentiviruses are known to have a long incubation period and can handle a larger capacity for a bigger gene, and it transduces more efficiently than either the adenovirus or the associated-adenovirus (AAV) vectors, Dr. Pattnaik said.

"A lentivirus will get almost 80 to 90% transduction, whereas the AAV vectors are closer to 50%," he said.

Initial results with an AAV vector showed the iPSCs would not transduce, which led the group to the lentivirus vector approach. Both the lentivirus and AAV vectors transfused in mice models, leaving the option open for future studies.

"Our study determined that the major pathogenic alteration affecting the RPE cells is the lack of functional Kir7.1 channel. We were also able to establish a genotype-phenotype (normal) correlation in an asymptomatic carrier individual. Use of carrier (control) hiPSC-RPE, from within the family, also accounts for modifier gene functions, epigenetic changes, and environmental contributions," the study authors noted.

While only a portion of the cells completely recovered, the finding suggests that the approach shows promise for future treatment, Dr. Pattnaik said.

TAKE-HOME

► **Though no gene therapies are approved for the treatment of LCA16, a study helped clarify that the disorder is a nonsense mutation and may be treated with breakthrough therapies.**

WHAT'S NEXT?

The FDA will not require animal studies for this approach, Dr. Pattnaik noted, because others

have already set the precedent that stem cell therapy is efficacious. Though no gene therapies are approved for the treatment of LCA16, this study helped to clarify the disorder as a nonsense mutation (and may be treated with breakthrough therapy, which has been approved), he said.

"We can go directly to the patient with this approach," he said.

Though this current paper did not address efficacy in animal models, the group has shown in preclinical data that their approach is working. ■

Reference

1. Shahi PW, Hermans D, Sinha D, et al. Gene augmentation and read-through rescue channelopathy in an iPSC-RPE model of congenital blindness. <https://doi.org/10.1101/485847>



Dr. Pattnaik

BIKASH PATTNAIK, PHD

E: pattnaik@wisc.edu

Dr. Pattnaik did not disclose any relevant financial disclosures.

For Products & Services and Recruitment advertising information, contact:
Joanna Shippoli at 800-225-4569, ext 2615 • Fax 440-756-5271 • Email: joanna.shippoli@ubm.com

PRODUCTS & SERVICES

BILLING SERVICES

Exclusive Ophthalmology Billers
 Expert Ophthalmology Billers
 Excellent Ophthalmology Billers
 Triple E = Everything gets paid



P.M. Medical Billing Corp
 EXCLUSIVE OPHTHALMOLOGY BILLING AND CONSULTING

100%

On Shore

Ophthalmology & Optometry Billing.

The First Original Exclusive Ophthalmology and Optometry National Billing and Consulting Company.

With 28 years of experience and over 45 medical billers plus who are certified Ophthalmic Techs, Ophthalmic assistants, Fundus photographers who also dual certified ophthalmic coders and billers. Proud to be an Executive of American Academy of Ophthalmology. Our clinical background and knowledge in Ophthalmology billing is second to none. That equates into a dramatic increase in your revenue. No more Bundling down coding, or denials.

We do not outsource your billing overseas. All billing done in our office in the U.S.A.

- Our In house Credentialing and Re-Credentialing Dept. Another added benefit as well as patient billing to increase revenue included in our services.
- Experts in Forensic Billing and old A/R clean up.
- Totally HIPA Compliant.
- We can offer you our own Practice Management software at no cost to you or we can VPN into your system if that's what you prefer.

Practice Management we work on:

NexTech, NexGen, MD Office, Medisoft, Advanced MD, Azalea, Cerner, Office Mate, TCMS, Revolution, Management Plus, QRS, Medware, Dr. Chrono, Centricity, Intergy, Echo, Care Cloud, eclinical, Allscripts, ADS and many more...

Our collection rate is consistently much higher than our competitors that results in a much higher revenue stream for your practice.

All of our clients are receiving the Mips bonus for the year.

Fee schedule analysis.

Our staff has years of Attendance at the AAO and ASCRS and attends all ongoing Ophthalmology billing and Practice Management continuing education classes. We are always knowledgeable and prepared for all government and commercial changes.

Call for free on site consultation. We will travel to you anytime to evaluate you're A/R and show you how we can increase your revenue.

Our Prestigious National Ophthalmology Clients reference list will be provided at your request.

PM Medical Billing will keep an EYE on your Billing so you can keep an EYE on your patients.

Call toll free at **1-888-PM-BILLING (1-888-762-4554)**

Email: info@pmbiller.com • Web: www.pmbiller.com • 24 hours: 516-830-1500 or 516-780-2895



FOCUSED MEDICAL BILLING
 A FULL SERVICE MEDICAL BILLING FIRM SPECIALIZING IN OPHTHALMOLOGY

Focused Medical Billing is a full service medical billing firm servicing all specialties of Ophthalmology. With our firm our focus is to maximize our client's revenue and dramatically decrease denials by utilizing over 20 years of Ophthalmology billing/coding experience and expertise. Our firm provides accurate clean claim submissions on first submissions with relentless A/R follow up to obtain a 98% collection rate that so many of our clients enjoy.

Services Include:

- Expert Coders: Billing to Primary, Secondary & Tertiary insurance companies
 - A/R Clean Up and analysis
 - Patient Billing
- Posting of all Explanation of benefits
- Credentialing & Re-Credentialing
 - Eligibility
- Fee Schedule Analysis
 - Monthly Reports
- No long term commitment or contract required
 - 100% HIPAA Compliant
 - Stellar letters of reference

Call us today for your free, no obligation consultation

Ph: 855-EYE-BILL ext. 802

Email: amay@focusedmedicalbilling.com • Web: www.focusedmedicalbilling.com

"You're focused on your patients, we're focused on you"

Narrow your candidate
 search *to the best.*

Place a recruitment ad in
Ophthalmology Times —
 in print or online.

Ophthalmology Times

Joanna Shippoli

Account Manager

440-891-2615

joanna.shippoli@ubm.com

ADVERTISE TODAY!

PRODUCTS & SERVICES

BILLING SERVICES



ECBC
EYE CARE BILLING CONSULTANTS

SEE YOUR PROFITS MORE CLEARLY

- Ophthalmology & Optometry billing only
- New York City based
- 25 years of experience

eyecarebillingconsultants.com
contact@eyecarebillingconsultants.com
(646) 828-8889

SPACE TO SHARE

Ophthalmologist to share offices with long-established ophthalmologist in **Danbury, CT 06811. OCT, Zeiss Fieldmaster etc \$2,250/mo** or adjoining office without equipment **\$1,750/m. 203 545 3539, mehrimd@aol.com**

CAREERS

GUAM

LIVE, PRACTICE AND TRAVEL FROM AN ISLAND IN THE WESTERN PACIFIC

Busy, Comprehensive Ophthalmology Practice on the U.S. Territory of Guam seeks to fill the following position:

ANTERIOR SEGMENT SURGEON and/or GLAUCOMA SPECIALIST

Practice is well established and growing; and offers an excellent practice environment with significant autonomy, minimal competition and minimal to no litigiousness in a friendly, moderately sized, uniquely Cosmopolitan island community of 200,000 residents.

Package includes pay based on a percentage of collections + starting support salary.

High volume clinic. Phaco skills necessary.

Glaucoma fellowship or Glaucoma skills helpful but not necessary.

Excellent opportunity for recent/soon to be graduate & seasoned surgeons alike. Inquiries will be kept strictly confidential until position is offered and accepted; at which point references will be checked.

3 MONTHS OF TIME OFF PER YEAR ARE INCLUDED

Please e-mail inquiries & C.V. including references to both admin@islandeyeguam.com & humblechuck@gmail.com



ISLAND EYE SPECIALISTS



Reach your target audience.

Our audience .

Ophthalmologists and allied eye care professionals. Contact me today to place your ad.

Joanna Shippoli

Account Manager

440-891-2773

joanna.shippoli@ubm.com

Recruitment Advertising Can Work For You!

Reach highly-targeted, market-specific business professionals, industry experts and prospects by placing your ad here!

Ophthalmology Times

CAREERS

GUAM

LIVE, PRACTICE AND TRAVEL FROM AN ISLAND IN THE WESTERN PACIFIC

Busy, Comprehensive Ophthalmology Practice on the U.S. Territory of Guam seeks to fill the following position:

RETINA SPECIALIST

Practice is well established and growing; and offers an excellent practice environment with significant autonomy, minimal competition and minimal to no litigiousness in a friendly, moderately sized, uniquely Cosmopolitan island community of 200,000 residents.

Unique practice opportunity with maximum autonomy.

Salary will be based on a percentage of Collections, however is negotiable.

Incentive based pay can easily reach \$800,000+

Extremely high income potential due to lack of Retina coverage.

Excellent opportunity for recent/soon to be graduate & seasoned surgeons alike.

Inquiries will be kept strictly confidential until position is offered and accepted; at which point references will be checked.

3 MONTHS OF TIME OFF PER YEAR ARE INCLUDED

Please e-mail inquiries & C.V. including references to both admin@islandeyeguam.com & humblechuck@gmail.com



ADVERTISE NOW!

Combine
Ophthalmology Times
Marketplace
print advertising with
our online offerings
to open up unlimited
potential.

VERMONT

THE
University of Vermont
MEDICAL CENTER

ACADEMIC NEURO-OPHTHALMOLOGIST

The Division of Ophthalmology at the University of Vermont College of Medicine, in alliance with the University of Vermont Medical Center, is seeking an academic neuro-ophthalmologist. This individual must have completed a board approved 3- or 4-year ophthalmology residency or a 3-year neurology residency and a clinical neuro-ophthalmology fellowship, and be board certified or board eligible, and eligible for medical licensure in the State of Vermont. The successful applicant will be appointed at the Assistant/Associate Professor level in the Clinical Scholar Pathway, commensurate with years of experience and accomplishments.

Duties will include providing clinical care to neuro-ophthalmology patients, teaching the principles of ophthalmology to medical students and undergraduate students in Allied Health programs, providing teaching experience for residents in training, developing basic and/or clinical research, and performing additional departmental and/or sectional administrative duties as assigned by the Chair of the Department of Surgery.

This is a full-time, 12 month, salaried, faculty appointment and carries with it attending staff privileges at The University of Vermont Medical Center. Salary is competitive and commensurate with ability and experience.

Located in Burlington, the University of Vermont Medical Center serves as Vermont's only academic medical center. Burlington is a vibrant community located on the shores of Lake Champlain, between the Adirondack and Green Mountains. With year-round recreational opportunities, safe communities and excellent schools, this progressive community has been frequently cited as one of the most livable cities in the U.S.

The University is especially interested in candidates who can contribute to the diversity and excellence of the academic community through their research, teaching, and/or service. Applicants are requested to include in their cover letter information about how they will further this goal.

The University of Vermont is an Equal Opportunity/Affirmative Action Employer. All qualified applicants will receive consideration for employment without regard to race, color, religion, sex, sexual orientation, gender identity, national origin, disability, protected veteran status, or any other category legally protected by federal or state law. The University encourages applications from all individuals who will contribute to the diversity and excellence of the institution.

Interested individuals should apply online at <https://www.uvmjobs.com/postings/32453> (position number 006035).

Inquiries may be directed to **Dr. Brian Kim** c/o **Kristin Allard** at Kristin.Allard@uvmhealth.org.

Strike a 'New Deal' for relief, recovery, reform in clinic

Demonstrate to most profitable patients how you want to become their practice of choice

By Donna Suter

President Franklin D. Roosevelt offered Americans the New Deal in March 1933, a series of economic programs aimed at combating the financial slump of the Great Depression. The stimulus package passed because President Roosevelt was focused on the three Rs: Relief, Recovery, and Reform.

Back then, consumers were uncertain of the economy and many expressed fears when asked about the future. Flash forward 86 years and not much has changed—many are still worried about their financial situations today.

However, ophthalmologists can make a “new deal” for their practices by using the three Rs as a template to alleviate financial woes and gain back profit for 2019.

1 RELIEF

Everyone wants relief from managed care, and the first step in achieving this goal is identifying a profitable patient. This patient, statically speaking, comes with a good vision plan.

Wouldn't it be a relief if the staff time necessary to keep up with all the demands placed on doctors and employees could be paired with acceptable profit? Ask your management team if it is possible to collect and analyze 24 months of raw data to determine your profitable patient.

If your practice management software generates real-time performance data and profit-and-loss data, use it to track total receivables back to your most profitable revenue sources.

Data, with proper analysis, can guide you into a future where tough decisions are clear. Demographic data are also available to tell what that profitable patient looks like.

Here is an example of how census data and

practice can be compared and used. Most of the United States' professional- and managerial-level workers are women. Women bring in half or more household income. Women make the majority of health-related decisions not only for themselves, but also for everyone in the household.

How are you catering to this demographic? Try treating this demographic with respect, and give her the option to upgrade to customized, VIP care.

2 RECOVERY

After he was sworn in, President Roosevelt ordered all banks to close. He then asked Congress to pass legislation guaranteeing that citizens would not lose their money if there was another financial crisis.

What bold move are you willing to make to recover? Can you convince patients that you are concerned about their vision, and not just your profit margin?

Employees may look at a payor group on their digital device and discretely sigh or a shoot a subtle behind-the-back-eye-roll to a coworker. Both nonverbal gestures are noticed by intuitive patients.

This patient might interpret this type of body language as animosity. The result is that he or she will purchase “just what my vision plan covers” or leave and purchase eye-wear online. He or she is also the surgical candidate who says they are going to seek a second opinion.

Small cues matter, and even the smallest—positive or negative—patient interaction counts.

TAKE-HOME

► *Practice management consultant Donna Suter shares how physicians can allay financial fears and gain back profit using the three Rs: Relief, Recovery, and Reform.*

IMPLEMENTING YOUR NEW DEAL

What are you willing to change to attract the profitable patient? Can you be quicker? Educate about options without being pushy? Not be a vision-plan hater?

Decide among your practice's doctors and

management team who to invite to a five-person think tank. This group will then identify the practice's internal strengths and weaknesses from the perspective of your most profitable patient demographic.

In order to do this, this team should be given access to historic financial graphs as well as asked to give input into a twelve-month budget. The budget will be used to implement the recommendations that your team ultimately suggests.

Which graphs? What financials? Surgical and patient visit graphs are a must. Graphs (A/R, gross charges, and net) showing extrapolations of increasing the practice's market share of this population group will help you decide how much money you can afford to budget for internal and external marketing.

3 REFORM

The dictionary defines the verb tense of “reform” as to make better or to improve by removing faults or abuses. Reform cannot happen in a murky environment.

What's the current “state of the practice”? Could you and all the key players agree on a brief positional statement? Do you all agree on strategic initiatives that might guide process improvement? What would you like to see improved in the next 12 months?

You now have your “new deal” going. In this environment of reformation, take bold action that demonstrates to your most profitable patient that you want to become his or her practice of choice.

Change does not happen overnight. If you are successful, the practice will undergo a metamorphosis. What will emerge is a realistic plan for the future. ■

DONNA SUTER

P: 423/545-4562 E: suter4pr@donnasuterconsulting.com

Suter is a business coach/trainer who specializes in the eye care field.

‘She Sees’ initiative promotes gender equity in eye health

Charity seeks to raise \$US20 million to address avoidable blindness in women, girls

By Ian Wishart



(FIGURE 1) Thol, 46, from Cambodia, had been completely blind for a year and a half. She had never seen her baby, Cheet, until this moment. Now that Thol can see again she is working and supporting the family, and the children are going to school.

Consider these scenarios. In every region of the world, a woman is more likely to be blind than a man.

Globally, 55% of the world's blind are women, which means more than 20 million women are blind and a further 120 million women are vision impaired. And staggeringly, four out of five of those women do not need to be blind.

Exacerbating the problem, 90% of women who are blind are living in poverty.

In low-income countries where cataract is responsible for most blindness, women are not able to access services with the same frequency as men. For example, the cataract surgical coverage among women in sub-Saharan Africa and South Asia is nearly always lower, sometimes only half that of men.

CLOSING THE GAP

With these statistics courtesy of the Australian-based international development organization, The Fred Hollows Foundation, the group is drawing attention to the problem and focusing

on closing that gap with a new global initiative called “She Sees.” The eye health charity is seeking to raise \$US20 million over the next five years to address the issue of avoidable blindness for women and girls. The She Sees initiative has at its heart the belief that women have an equal right to sight.

The foundation—which was formed 26 years ago by the late eye surgeon, Fred Hollows, MD, and his wife, Gabi—works in more than 25 countries and has restored sight to more than 2.5 million people around the world. It registered in the United States last year, and is funded through the generosity of public donations as well as international development agencies such as USAID (www.usaid.gov).

FOR MORE INFORMATION

She Sees Initiative

www.hollows.org/shesees

Restoring Women's Sight Report

www.hollows.org/Upload/FHF/Media/2018-She-Sees-EUI.pdf

The organization's aim is simple—to end avoidable blindness. It does that by working in developing countries with local partners and training local doctors, nurses, community health workers, and teachers to strengthen the health systems and provide comprehensive eye care to some of the poorest and most marginalized people.

The foundation has witnessed the disparity in access to care for women and girls and decided to do something about it.

Before creating the She Sees initiative, the foundation commissioned a landmark global report, *Restoring Women's Sight*, prepared by the Economist Intelligence Unit. The report is a flagship study into why women are more likely to be blind and the impacts of women being disproportionately represented in the statistics.

Some of the key reasons affecting women's eye health include:

■ **BIOLOGY** – women generally live longer so they are more likely to experience some eye diseases like cataract.

■ **COST** – the treatment of men, who are



(FIGURE 2) Francine, 76, is from the Eastern Province of Rwanda and had been totally blind for more than three years. A widow for 30 years, she had a lot of difficulty working and cooking for herself, which made her life miserable. It was left to Francine's neighbor to take care of her, take her to church and regularly visit her.



(FIGURE 3) When Ciku Mathenge, MD, successfully removed Francine's cataracts she cried with joy. Francine said: "I am very happy to see my home, thank you. My house is older than before! I will be able to cook again. I am happy to work." Francine's local community was shocked but thrilled that she could see again and came out to celebrate. (Images courtesy of Michael Amendolia/The Fred Hollows Foundation)

more often the main income earners in developing countries, is prioritized. Women who do not have their own income and decision-making power may also face further barriers.

■ **CULTURAL FACTORS** – In many countries, women are unable to travel to medical appointments unaccompanied, reducing the access to services.

■ **WOMEN ARE CARERS** – women are twice as likely as men to be blinded by trachoma because it passes from children to mothers.

Vision impairment and blindness have far-reaching implications not just for the women affected, but also for their families, and for progress toward many of the sustainable development goals, such as gender equality, and decent work and economic growth.

The Economist Intelligence Unit report looked at the social implications of blindness, the psychological well-being, the income earning potential, and on women's capacity to participate

actively in society. The findings provide a way forward for closing the gender gap and ensuring women have better access to services.

Through the She Sees initiative, the organization is determined to advance its gender-focused work and help deliver high-quality programs that work to close the gender gap in blindness around the world.

As a leader in affordable, accessible eye care, the foundation's goal is to end gendered discrimination in eye health and to empower women and girls with sight.

The foundation has developed a multifaceted approach to this, starting with placing women and girls firmly at the center of programs, services, partnerships, and global advocacy work. It wants to ensure all women and girls can access eye health care and can effectively engage with services.

WHERE WORK, LIVE

On top of that, the organization is developing creative programs specifically reaching out to women where they work and where they live.

An example of this is in Pakistan and Bangladesh where the foundation is working with local hospitals and health agencies to train outreach health workers who deliver maternal and child health services in eye care so they can find and direct women and children with eye health issues to local services.

The foundation is also training more women as health workers because in many regions women are more likely to access services when they are run by women.

The organization has also set up vision corners and eye programs in Bangladeshi garment factories and in cottage industries in countries such as Vietnam.


By taking programs to places where so many women work it means they can access eye care easily which allows them to continue to earn an income to support their children and families.

The foundation is committed to empowering women and ensuring women are represented in leadership positions across all eye health workforce groups, and it encourages others in the eye health sector to also help address the issue to change the lives of women and girls and help break the cycle of poverty caused by blindness and vision impairment. ■



IAN WISHART
E: ffhf@hollows.org
Wishart is chief executive officer of The Fred Hollows Foundation.

Giving new meaning to seeing is believing



“I really want to thank Dr. Conway. When you say ‘I may see the doctor now,’ I can *REALLY* see the doctor!”

Artwork by Jan Carter

Advertiser Index

Advertiser	Page
BAUSCH + LOMB 800/227-1427 www.bausch.com	CV4
CLEARSIDE BIOMEDICAL www.clearsidebio.com	13
SHIRE OPHTHALMIC 800/828-2088 www.shire-eyes.com	5-7
TTI MEDICAL 800/322-7373 www.ttimedical.com	21

This index is provided as an additional service. The publisher does not assume any liability for errors or omissions.

OPHTHALMOLOGY TIMES (Print ISSN 0193-032X, Digital ISSN 2150-7333) is published semimonthly except for one issue in Jan, May, Aug and Dec (20 issues yearly) by MultiMedia Healthcare LLC 325 W 1st St STE 300 Duluth MN 55802. Subscription rates: \$200 for one year in the United States & Possessions, Canada and Mexico; all other countries \$263 for one year. Pricing includes air-expedited service. Single copies (prepaid only): \$13 in the United States & Possessions, Canada and Mexico; \$20 all other countries. Back issues, if available are \$25 in the U.S. \$ Possessions; \$30 in Canada and Mexico; \$35 in all other countries. Include \$6.50 per order plus \$2 per additional copy for U.S. postage and handling. If shipping outside the U.S., include an additional \$10 per order plus \$5 per additional copy. **Periodicals postage paid** at Duluth, MN 55806 and additional mailing offices. **POSTMASTER:** Please send address changes to OPTHALMOLOGY TIMES, P.O. Box 6009, Duluth, MN 55806-6009. Canadian G.S.T. number: R-124213133RT001, Publications Mail Agreement Number 40612608. Return undeliverable Canadian addresses to: IMEX Global Solutions, PO Box 25542 London, ON N6C 6B2 CANADA. Printed in the U.S.A.

© 2019 MultiMedia Healthcare LLC. All rights reserved. No part of this publication may be reproduced or transmitted in any form or by any means, electronic or mechanical including by photocopy, recording, or information storage and retrieval without permission in writing from the publisher. Authorization to photocopy items for internal/educational or personal use, or the internal/educational or personal use of specific clients is granted by MultiMedia Healthcare LLC for libraries and other users registered with the Copyright Clearance Center, 222 Rosewood Dr. Danvers, MA 01923, 978-750-8400 fax 978-646-8700 or visit <http://www.copyright.com> online. For uses beyond those listed above, please direct your written request to Permission Dept. fax 732-647-1104 or email: Jillyn.Frommer@ubm.com

in case you missed it

Stable surgery may help better predict effective IOL position
PAGE 14

Clinical update for fluocinolone acetamide implant **PAGE 20**

Novel vision-screening tools for children worldwide **PAGE 25**

Cut yourself a ‘New Deal’: Relief, recovery, and reform
PAGE 31

next issue...

► **Special Report:**
New initiatives in refractive surgery


► **ARVO View:**
A look to this year’s meeting in Vancouver



IOL design offers premium results
OPHTHALMOLOGYTIMES.COM/CATARACTSUPPORT

Corneal inlay choice for presbyopia
OPHTHALMOLOGYTIMES.COM/INLAY

Let Us Be Your *Eyes and Ears*



Introducing EyePod: Podcasts from *Ophthalmology Times*

This new audible resource from *Ophthalmology Times* engages with key opinion leaders in interviews about the latest innovations in the areas of surgery, clinical diagnosis, pharmaceutical advancements, research, and technology, plus practice management.

Hear the voices of ophthalmic innovation.

OphthalmologyTimes.com/EyePod

TRULIGN[®]
POSTERIOR CHAMBER INTRAOCULAR LENS **TORIC**

Bringing **astigmatism**
AND presbyopia
into focus.



TRULIGN[®] Toric IOL offers the critical advantages your patients need:
Full range of vision¹ | Excellent stability²⁻⁴ | Minimized dysphotopias¹

FROM HERE ON OUT, IT'S TRULIGN.

TRULIGN.COM

INDICATIONS FOR USE: The TRULIGN[®] toric posterior chamber intraocular lens (IOL) is intended for primary implantation in the capsular bag of the eye for the visual correction of aphakia and postoperative refractive astigmatism secondary to removal of a cataractous lens in adult patients with or without presbyopia who desire reduction of residual refractive cylinder with increased spectacle independence and improved uncorrected near, intermediate and distance vision. **WARNINGS:** Careful preoperative evaluation and sound clinical judgement should be used by the surgeon to decide the risk / benefit ratio before implanting a lens in a patient. Rotation of toric lenses away from their intended axis can reduce their effectiveness, and misalignment can increase postoperative refractive cylinder. The TRULIGN[®] Toric IOL should only be repositioned when the refractive needs of the patient outweigh the potential risks inherent in any surgical reintervention into the eye. Unlike most other IOLs, the TRULIGN[®] Toric IOL optic has hinges connecting it to the haptic; please see adverse events section below for more information. **PRECAUTIONS:** The safety and effectiveness of the TRULIGN[®] Toric intraocular lenses have not been substantiated in patients with preexisting ocular conditions and intraoperative complications. Long-term stability in the human eye has not been established; therefore postoperative monitoring after implant should be performed on a regular basis. Lens rotation less than 5° may not warrant reorientation. Do not resterilize this intraocular lens by any method. Do not store lenses at temperatures over 45°C (113°F). Careful preoperative evaluation and sound clinical judgment should be used by the surgeon to decide the benefit/risk ratio before implanting a lens in a patient with conditions as outlined in the TRULIGN[®] Toric IOL directions for use. **ADVERSE EVENTS:** The incidence of adverse events experienced during the clinical trial was comparable to or lower than the incidence reported in the historic control ("FDA grid") population. As with any surgical procedure, risk is involved. Vaulting is a post-operative adverse event where the TRULIGN[®] Toric IOL optic hinges move into and remain in a displaced configuration. If vaulting occurs, please see Directions for Use for a detailed listing of symptoms, information regarding diagnosis, potential causes, and sequelae. Physicians should consider the characteristics of each individual vaulting case prior to determining the appropriate treatment. Data on long-term follow-up after treatment of vaulting is not available. **ATTENTION:** Refer to the Directions for Use labeling for a complete listing of indications, warnings and precautions, clinical trial information, etc. **CAUTION: Federal (USA) law restricts this device to the sale by or on the order of a physician.**

1. TRULIGN Toric IOL Directions for Use. 2. Data on file, Bausch & Lomb Incorporated. Study 650. 3. AcrySof IQ Toric Directions for Use. 4. Tecnis Toric Directions for Use.

^{®/™} are trademarks of Bausch & Lomb Incorporated or its affiliates. All other brand/product names are trademarks of their respective owners.

©2017 Bausch & Lomb Incorporated. CRT.0028.USA.17

LONG TERM VISION | FOR YOUR PATIENTS | FOR YOUR PRACTICE

BAUSCH + LOMB